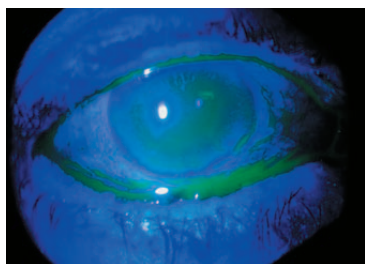


► OphthalmologyTimes.com

Surgery

## TIPS FOR MANAGING CONJUNCTIVAL CHALASIS CASES



**AMONG THE** mechanical problems related to dry eye is conjunctivochalasis—the Tenon’s capsule condition in which long-term chronic inflammation and dry eye causes dissolution of normal Tenon’s fascia. The conjunctiva becomes loose, shortening the inferior fornix tear reservoir, where half the tear volume resides in healthy eyes. Neel R. Desai, MD, follows a two-pronged approach to the disorder.

( See story on page 11 : Dry eye relief )

Focal Points

## TRENDS: HOW RETINAL SURGEONS PRACTICE IN 2018

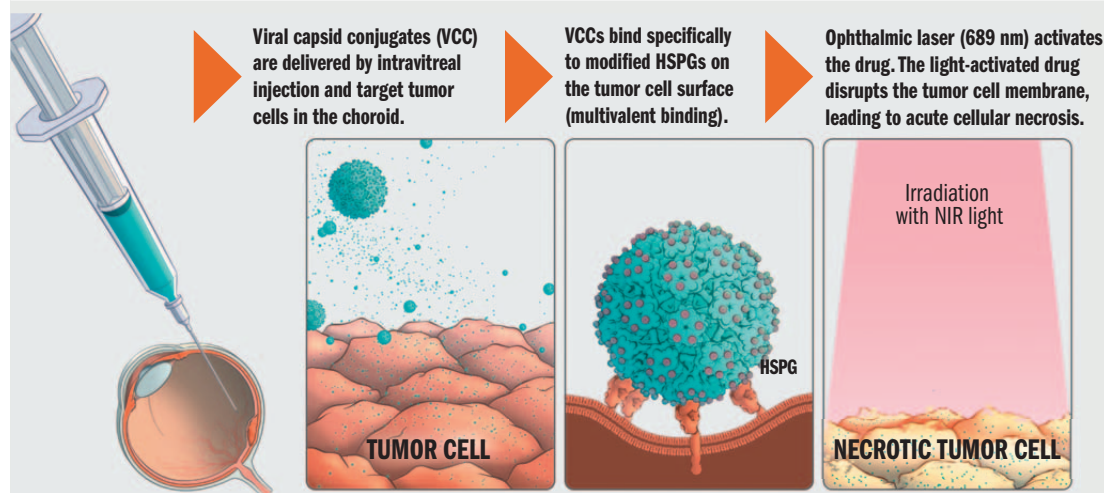
**FROM FIRST-LINE** choice in anti-vascular endothelial growth factor therapy for age-related macular degeneration to learning a new surgical technique via video, the 2018 Global Trends in Retina survey results are out. Rishi P. Singh, MD, shares the highlights.

( See story on page 8 : Global trends )

# TARGETED THERAPY FOR OCULAR MELANOMA

Novel light-activated drug therapy disrupts tumor cell membrane, causing acute cellular necrosis

### IN VIEW



**MECHANISM OF ACTION:** Targeted acute tumor cellular necrosis upon light activation. The novel targeted therapy, developed from the work of John T. Schiller, PhD, at the National Institutes of Health, consists of a viral capsid conjugated to a dye. The drug is given as an intravitreal injection and the viral capsid binds specifically to modified HSPG found on the surface of malignant tumor cells. About 6 to 8 hours after the injection, the drug is activated by laser application to the tumor using the same wavelength and fluence used for photodynamic therapy. The photoactivation of the drug leads to tumor cell necrosis. (Images courtesy of Aura Biosciences Inc.)

By Michelle Dalton, ELS;  
Reviewed by Amy C. Scheffler, MD


**LIGHT-ACTIVATED AU-011** has the potential to be the first targeted therapy ever developed for the primary treatment of ocular melanoma, the most common primary cancer of the eye, said Amy C. Scheffler, MD, with Retina Consultants of Houston.

People diagnosed with ocular melanoma confront “an array of poor treatment options, which often result in severe vision loss, removal of the eye, and in about half of all cases, metastasis to the liver, where the disease is nearly always fatal,” according to Aura Biosciences, which developed this light-activated technology.

AU-011 is a first-in-class targeted therapy, a novel protein capsid-dye conjugate recombinantly derived from the capsid proteins of the papilloma virus; the FDA has already granted Fast Track Designation and Orphan Drug Designation, recognizing that there are no FDA-approved therapies and that the disease is serious and life-threatening, Dr. Scheffler said.

The mechanism of action of AU-011 is targeted acute tumor cellular necrosis upon light activation.

( Continues on page 21 : Light-activated )



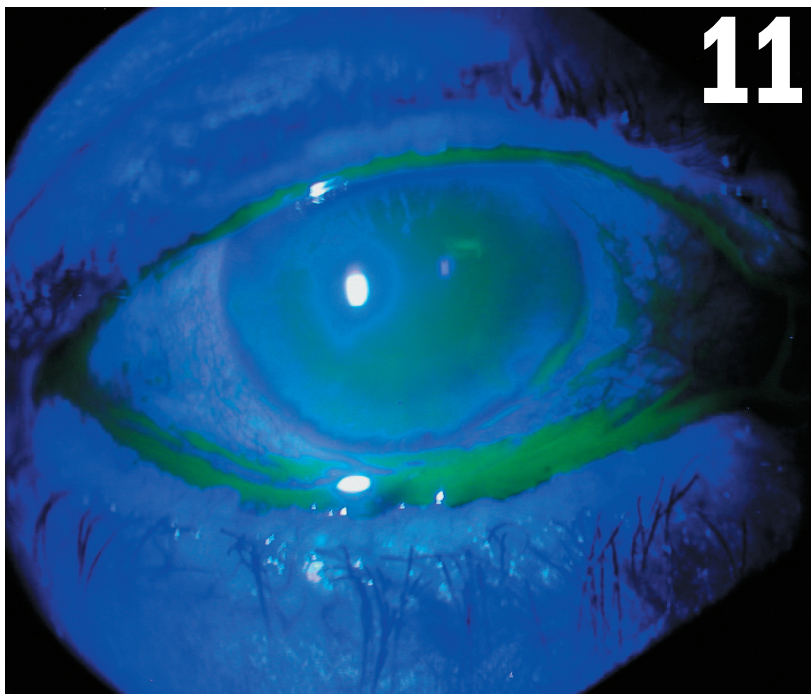
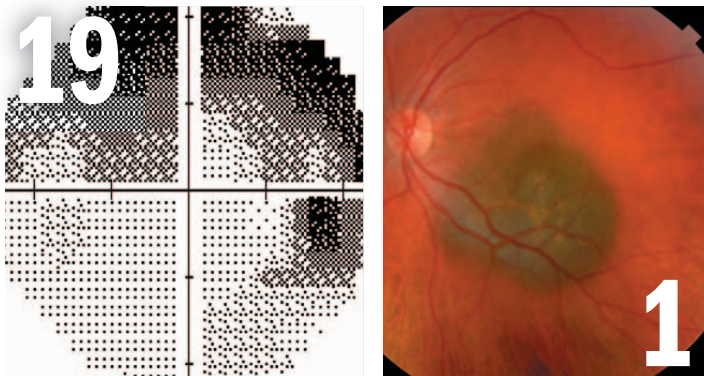
reVolutionizing  
toric design

enVista®  
One-piece Hydrophobic Acrylic Toric Intraocular Lens

®/™ are trademarks of Bausch & Lomb Incorporated or its affiliates. All other brand/product names are trademarks of the respective owners. © 2018 Bausch & Lomb Incorporated. EVT.0020.USA.18

LONG TERM VISION | FOR YOUR PATIENTS | FOR YOUR PRACTICE

**BAUSCH + LOMB**



## Drug Therapy

### 21 TARGETED LIGHT THERAPY ON HORIZON FOR OCULAR MELANOMA

The light-activated drug disrupts the tumor cell membrane, causing necrosis.

## Special Report

### 32 MICROSCOPE-INTEGRATED OCT VITAL TO GENE THERAPY

Tool allows surgeons to visualize retinal anatomy, and it also provides them with real-time tissue-interaction feedback.

## Practice Management

### 40 THE BEST TOOLS FOR PRESCRIPTION MANAGEMENT

Use an array of web-based apps and programs to improve patient adherence.

## In This Issue

4 EDITORIAL

8 FOCAL POINTS

39 MARKETPLACE

## What's Trending

See what the ophthalmic community is reading on [OphthalmologyTimes.com](http://OphthalmologyTimes.com)

### 1 Orbital pathologies and trauma

[OphthalmologyTimes.com/OrbitalTrauma](http://OphthalmologyTimes.com/OrbitalTrauma)

### 2 Hey, chocolate chip cookie fans!

[OphthalmologyTimes.com/Cookies](http://OphthalmologyTimes.com/Cookies)

### 3 SCUT trial delves into corticosteroid use for bacterial corneal ulcers

[OphthalmologyTimes.com/SCUTtrial](http://OphthalmologyTimes.com/SCUTtrial)

### 4 Fungal keratitis diagnosis: Beyond the slit lamp

[OphthalmologyTimes.com/FungalKeratitis](http://OphthalmologyTimes.com/FungalKeratitis)

## Digital App

Introducing the *Ophthalmology Times* app for iPad and iPhone. Download it for free today at [OphthalmologyTimes.com/OTapp](http://OphthalmologyTimes.com/OTapp).



## eReport

Sign up for *Ophthalmology Times*' weekly eReport at [Ophthalmologytimes.com/eReport](http://Ophthalmologytimes.com/eReport).



## Video



Watch Vicente Anido, CEO of Aerie, share an update on the company, by visiting [OphthalmologyTimes.com/Anido](http://OphthalmologyTimes.com/Anido)

## Facebook

Like *Ophthalmology Times* at [Facebook.com/OphthalmologyTimes](https://www.facebook.com/OphthalmologyTimes)

# It's time to unplug

Sometimes it's best to take a deep breath and pause for a bit



**By Peter J. McDonnell, MD**

director of the Wilmer Eye Institute, Johns Hopkins University School of Medicine, Baltimore, and chief medical editor of *Ophthalmology Times*.

He can be reached at 727 Maumenee Building 600 N. Wolfe St. Baltimore, MD 21287-9278  
Phone: 443/287-1511 Fax: 443/287-1514  
E-mail: pmcdonn1@jhmi.edu

**ROMAN EMPEROR** Marcus Aurelius ruled most of the known world from 161 to 180 AD. During this time he wrote a book composed of his meditations. He meant this to be for his eyes only, and left orders that it be destroyed upon his death. But rather than burn the book, his successors decided that it was so special that it must be preserved and published.

What kind of person writes a book only for himself? In this instance, it is a man who wishes to ponder key questions about how he is using his life. As an example, in one meditation he asks himself: "To what purpose, then, am I now using my soul?" (Marcus Aurelius' *Meditations* Book V, No. 11).

**'If we are never still, how can we connect with our soul and reflect on our purpose in life?'**

How do we answer that question? It requires taking time for pondering, listening, reflecting, soul-searching. For we who are living two millennia after Marcus Aurelius, those things don't happen very easily: taking time, pondering, listening, reflecting, searching.

Four years ago, University of Virginia Professor Timothy Wilson, PhD, directed a study in which men and women were encouraged to simply sit still and let their minds wander for 15 minutes.<sup>1</sup>

Women and men both failed. In minutes, most were wondering if they'd missed any calls or texts, or if they'd gotten any email. Was there something they should be working on? What's new on Facebook? What was next on the calendar? They reported that they simply could not comply with the professor's request!

Wilson wondered: Were people so uncomfortable with stillness that they would prefer negative stimulation instead?

The men and women in the study were given these options for their 15 minutes: sit quietly, or shock yourself. A device hooked to a 9-volt battery gave a mild shock when a subject pressed his or her button. One-fourth of the women and two-thirds of men chose to press the button. One man hit it 190 times in 15 minutes.

If we are never still, how can we connect with our soul and reflect on our purpose in life?

I do not know whether any ophthalmologists were included in this psychology experiment. But I do believe that the demands placed on us, the need for us to efficiently care for so many patients in our clinics and our operating rooms, plus by the errands and demands we face when we leave the office, have taught us to be busy almost every second of our lives. This training makes it very difficult for ophthalmologists to silence our devices, be by ourselves, be still and simply reflect upon how we are leading our lives and, as Marcus Aurelius would put it, using our souls.

Have you spent 15 minutes recently doing nothing but pondering whether you are putting your soul to its best use? Would you agree, dear reader, that this is a question worth asking and answering? ■

## Reference

1. Wilson et al. Just think: The challenges of the disengaged mind. *Science*. 2014;345:75-77.

CHECK OUT  
**XIIDRA-ECP.COM**

### STUDY 1

Studied 3 concentrations  
(0.1%, 1.0%, 5.0%)

**230**  
PATIENTS

**12**  
WEEKS

### STUDY 2

Phase 3

**588**  
PATIENTS

**12**  
WEEKS

### STUDY 3

Phase 3

**718**  
PATIENTS

**12**  
WEEKS

### STUDY 4

Phase 3

**711**  
PATIENTS

**12**  
WEEKS

### SONATA

Phase 3

**331**  
PATIENTS

**1**  
YEAR



# XIIDRA HAS BEEN STUDIED IN A LARGE DRY EYE DISEASE CLINICAL TRIAL PROGRAM

**MORE THAN 2,500 PATIENTS  
ACROSS 5 CLINICAL TRIALS**

**Xiidra is the first and only eye drop FDA-approved to treat both the signs and symptoms of Dry Eye Disease. It has been studied in more patients than any other pivotal clinical trial program for a prescription Dry Eye Disease treatment to date. Learn more about why you and your patients should give Xiidra a try.**

**Check out [Xiidra-ECP.com](http://Xiidra-ECP.com)**

#### **Indication**

Xiidra® (lifitegrast ophthalmic solution) 5% is indicated for the treatment of signs and symptoms of dry eye disease (DED).

#### **Important Safety Information**

Xiidra is contraindicated in patients with known hypersensitivity to lifitegrast or to any of the other ingredients.

In clinical trials, the most common adverse reactions reported in 5-25% of patients were instillation site irritation, dysgeusia and reduced visual acuity. Other adverse reactions reported in 1% to 5% of the patients were blurred vision, conjunctival hyperemia, eye irritation, headache, increased lacrimation, eye discharge, eye discomfort, eye pruritus and sinusitis.

To avoid the potential for eye injury or contamination of the solution, patients should not touch the tip of the single-use container to their eye or to any surface.

Contact lenses should be removed prior to the administration of Xiidra and may be reinserted 15 minutes following administration.

Safety and efficacy in pediatric patients below the age of 17 years have not been established.

For additional safety information, see accompanying Brief Summary of Safety Information on the adjacent page and Full Prescribing Information on [Xiidra-ECP.com](http://Xiidra-ECP.com).

©2018 Shire US Inc., Lexington, MA 02421. 1-800-828-2088. All rights reserved. SHIRE and the Shire Logo are trademarks or registered trademarks of Shire Pharmaceutical Holdings Ireland Limited or its affiliates. Marks designated ® and ™ are owned by Shire or an affiliated company. S39580 05/18

**Shire**



## BRIEF SUMMARY:

Consult the Full Prescribing Information for complete product information.

## INDICATIONS AND USAGE

Xiidra® (lifitegrast ophthalmic solution) 5% is indicated for the treatment of the signs and symptoms of dry eye disease (DED).

## DOSAGE AND ADMINISTRATION

Instill one drop of Xiidra twice daily (approximately 12 hours apart) into each eye using a single-use container. Discard the single-use container immediately after using in each eye. Contact lenses should be removed prior to the administration of Xiidra and may be reinserted 15 minutes following administration.

## CONTRAINDICATIONS

Xiidra is contraindicated in patients with known hypersensitivity to lifitegrast or to any of the other ingredients in the formulation.

## ADVERSE REACTIONS

### Clinical Trials Experience

Because clinical studies are conducted under widely varying conditions, adverse reaction rates observed in clinical studies of a drug cannot be directly compared to rates in the clinical trials of another drug and may not reflect the rates observed in practice. In five clinical studies of dry eye disease conducted with lifitegrast ophthalmic solution, 1401 patients received at least 1 dose of lifitegrast (1287 of which received lifitegrast 5%). The majority of patients (84%) had  $\leq 3$  months of treatment exposure. 170 patients were exposed to lifitegrast for approximately 12 months. The majority of the treated patients were female (77%). The most common adverse reactions reported in 5-25 % of patients were instillation site irritation, dysgeusia and reduced visual acuity. Other adverse reactions reported in 1% to 5% of the patients were blurred vision, conjunctival hyperemia, eye irritation, headache, increased lacrimation, eye discharge, eye discomfort, eye pruritus and sinusitis.

### Postmarketing Experience

The following adverse reactions have been identified during postapproval use of Xiidra. Because these reactions are reported voluntarily from a population of uncertain size, it is not always possible to reliably estimate their frequency or establish a causal relationship to drug exposure.

Rare cases of hypersensitivity, including anaphylactic reaction, bronchospasm, respiratory distress, pharyngeal edema, swollen tongue, and urticaria have been reported. Eye swelling and rash have been reported.

## USE IN SPECIFIC POPULATIONS

### Pregnancy

There are no available data on Xiidra use in pregnant women to inform any drug associated risks. Intravenous (IV) administration of lifitegrast to pregnant rats, from pre-mating through gestation day 17, did not produce teratogenicity at clinically relevant systemic exposures. Intravenous administration of lifitegrast to pregnant rabbits during organogenesis produced an increased incidence of omphalocele at the lowest dose

tested, 3 mg/kg/day (400-fold the human plasma exposure at the recommended human ophthalmic dose [RHOD], based on the area under the curve [AUC] level). Since human systemic exposure to lifitegrast following ocular administration of Xiidra at the RHOD is low, the applicability of animal findings to the risk of Xiidra use in humans during pregnancy is unclear.

### Animal Data

Lifitegrast administered daily by intravenous (IV) injection to rats, from pre-mating through gestation day 17, caused an increase in mean preimplantation loss and an increased incidence of several minor skeletal anomalies at 30 mg/kg/day, representing 5,400-fold the human plasma exposure at the RHOD of Xiidra, based on AUC. No teratogenicity was observed in the rat at 10 mg/kg/day (460-fold the human plasma exposure at the RHOD, based on AUC). In the rabbit, an increased incidence of omphalocele was observed at the lowest dose tested, 3 mg/kg/day (400-fold the human plasma exposure at the RHOD, based on AUC), when administered by IV injection daily from gestation days 7 through 19. A fetal No Observed Adverse Effect Level (NOAEL) was not identified in the rabbit.

### Lactation

There are no data on the presence of lifitegrast in human milk, the effects on the breastfed infant, or the effects on milk production. However, systemic exposure to lifitegrast from ocular administration is low. The developmental and health benefits of breastfeeding should be considered, along with the mother's clinical need for Xiidra and any potential adverse effects on the breastfed child from Xiidra.

### Pediatric Use

Safety and efficacy in pediatric patients below the age of 17 years have not been established.

### Geriatric Use

No overall differences in safety or effectiveness have been observed between elderly and younger adult patients.

## NONCLINICAL TOXICOLOGY

### Carcinogenesis, Mutagenesis, Impairment of Fertility

**Carcinogenesis:** Animal studies have not been conducted to determine the carcinogenic potential of lifitegrast.

**Mutagenesis:** Lifitegrast was not mutagenic in the *in vitro* Ames assay. Lifitegrast was not clastogenic in the *in vivo* mouse micronucleus assay. In an *in vitro* chromosomal aberration assay using mammalian cells (Chinese hamster ovary cells), lifitegrast was positive at the highest concentration tested, without metabolic activation.

**Impairment of fertility:** Lifitegrast administered at intravenous (IV) doses of up to 30 mg/kg/day (5400-fold the human plasma exposure at the recommended human ophthalmic dose (RHOD) of lifitegrast ophthalmic solution, 5%) had no effect on fertility and reproductive performance in male and female treated rats.



Manufactured for: Shire US Inc., 300 Shire Way, Lexington, MA 02421. For more information, go to [www.Xiidra.com](http://www.Xiidra.com) or call 1-800-828-2088. Marks designated ® and ™ are owned by Shire or an affiliated company. ©2018 Shire US Inc. SHIRE and the Shire Logo are trademarks or registered trademarks of Shire Pharmaceutical Holdings Ireland Limited or its affiliates. Patented: please see <https://www.shire.com/legal-notice/product-patents> Last Modified: 01/2018 S33769

OFFICIAL PUBLICATION SPONSOR OF



## Ophthalmology Times

AUGUST 2018 ■ VOL. 43, NO. 13

### CONTENT

**Chief Medical Editor** Peter J. McDonnell, MD

**Group Editorial Director** Sheryl Stevenson  
sheryl.stevenson@ubm.com 440/891-2625

**Associate Editor** Julianne Mobilian  
julianne.mobilian@ubm.com 440/891-2608

**VP, Content & Strategy** Sara Michael  
sara.michael@ubm.com 203/523-7107

**Design Director** Robert McGarr

**Senior Graphic Designer** Lecia Landis

**Graphic Designer** Steph Bentz

**Anterior Segment Techniques**  
Ernest W. Kormmehl, MD

**coding.doc** L. Neal Freeman, MD, MBA

**Money Matters** John J. Grande, Traudy F. Grande,  
and John S. Grande, CFPs®

**Neuro-Ophthalmology** Andrew G. Lee, MD

**Ophthalmic Heritage** Norman B. Medow, MD

**Tech Talk** H. Jay Wisnicki, MD

**Uveitis Update**  
Emmett T. Cunningham Jr., MD, PhD, MPH

### PUBLISHING /ADVERTISING

**EVP, Managing Director** Georgiann DeCenzo  
georgiann.decenzo@ubm.com 440/891-2778

**Group Publisher** Leonardo Avila  
leonardo.avila@ubm.com 302/239-5665

**Publisher** Erin Schlussek Stever  
erin.schlussek@ubm.com 215/962-5399

**National Account Manager** Cherie Pearson  
cherie.pearson@ubm.com 609/636-0172

**Account Manager, Recruitment Advertising**  
Joanna Shippoli joanna.shippoli@ubm.com  
440/891-2615

**VP, Digital Sales Development** Christy Tetterton  
christy.tetterton@ubm.com 212/600-3160

**Reprints** Licensing and Reuse of Content: Contact our  
official partner, Wright's Media, about available usages,  
license fees, and award seal artwork at Advanstar@  
wrightsmedia.com for more information. Please note  
that Wright's Media is the only authorized company that  
we've partnered with for Advanstar UBM materials.

**Permissions/International Licensing**  
Jillyn Frommer jillyn.frommer@ubm.com  
732/346-3007

### PRODUCTION

**Production Director** Karen Lenzen  
klenzen@hcl.com 218/740-6371

### AUDIENCE DEVELOPMENT

**Audience Development Manager** Kelly Kemper  
kelly.kemper@ubm.com 612/253-2039

UBM Medica provides certain customer contact data (such as customers' names, addresses, phone numbers, and e-mail addresses) to third parties who wish to promote relevant products, services, and other opportunities that may be of interest to you. If you do not want UBM Medica to make your contact information available to third parties for marketing purposes, simply call toll-free 866-529-2922 between the hours of 7:30 a.m. and 5 p.m. CST and a customer service representative will assist you in removing your name from UBM Medica's lists. Outside the U.S., please phone 218-740-6477.

Ophthalmology Times does not verify any claims or other information appearing in any of the advertisements contained in the publication, and cannot take responsibility for any losses or other damages incurred by readers in reliance of such content.

Ophthalmology Times cannot be held responsible for the safekeeping or return of unsolicited articles, manuscripts, photographs, illustrations or other materials.

Ophthalmology Times is a member of the Association of Independent Clinical Publications Inc.

**Library Access** Libraries offer online access to current and back issues of Ophthalmology Times through the EBSCO host databases.  
**To subscribe**, call toll-free 888-527-7008. Outside the U.S. call 218-740-6477.

PRINTED IN  
U.S.A.

## Ophthalmology Times MISSION STATEMENT

Ophthalmology Times is a physician-driven media brand that presents cutting-edge advancements and analysis from around the world in surgery, drug therapy, technology, and clinical diagnosis to elevate the delivery of progressive eye health from physician to patient.

Ophthalmology Times' vision is to be the leading content resource for ophthalmologists.

Through its multifaceted content channels, Ophthalmology Times will assist physicians with the tools and knowledge necessary to provide advanced quality patient care in the global world of medicine.

**CHIEF MEDICAL EDITOR** Peter J. McDonnell, MD Wilmer Eye Institute Johns Hopkins University Baltimore, MD

### ASSOCIATE MEDICAL EDITORS

**Dimitri Azar, MD**

University of Illinois, Chicago  
Chicago, IL

**Ernest W. Kormmehl, MD**

Harvard & Tufts Universities  
Boston, MA

**Joan Miller, MD**

Massachusetts Eye & Ear  
Infirmiry  
Harvard University  
Boston, MA

**Randall Olson, MD**

University of Utah  
Salt Lake City, UT

**Robert Osher, MD**

University of Cincinnati  
Cincinnati, OH

**Anne L. Coleman, MD**

Jules Stein Eye Institute, UCLA  
Los Angeles, CA

**Robert K. Maloney, MD**

Los Angeles, CA

#### Anterior Segment/Cataract Cornea/External Disease

**Ashley Behrens, MD**

Wilmer Eye Institute, Johns Hopkins University  
Baltimore, MD

**Elizabeth A. Davis, MD**

University of Minnesota,  
Minneapolis, MN

**Uday Devgan, MD**

Jules Stein Eye Institute, UCLA  
Los Angeles, CA

**Richard S. Hoffman, MD**

Oregon Health & Science University  
Portland, OR

**Samuel Masket, MD**

Jules Stein Eye Institute, UCLA  
Los Angeles, CA

**Bartly J. Mondino, MD**

Jules Stein Eye Institute, UCLA  
Los Angeles, CA

**Mark Packer, MD**

Boulder, CO

**Michael Raizman, MD**

Massachusetts Eye & Ear, Harvard University Boston, MA

**Ehsan "Ethan" Sadri, MD, FACS**

Newport Beach, CA

**Michael Snyder, MD**

Cincinnati Eye Institute  
Cincinnati, OH

**Farrell "Toby" Tyson, MD**

Cape Coral, FL

#### Glaucoma

**Robert D. Fechtner, MD**

SUNY Upstate Medical University  
Syracuse, NY

**Neeru Gupta, MD**

University of Toronto  
Toronto, Canada

**Richard K. Parrish II, MD**

Bascom Palmer Eye Institute, University of Miami  
Miami, FL

**Robert Ritch, MD**

New York Eye & Ear Infirmiry  
New York, NY

**Joel Schuman, MD**

NYU Langone Medical Center  
New York, NY

**Kuldev Singh, MD**

Stanford University  
Stanford, CA

**Joshua D. Stein, MD**

University of Michigan  
Ann Arbor, MI

**Robert N. Weinreb, MD**

Hamilton Glaucoma Center  
University of California, San Diego

#### Neuro-Ophthalmology

**Andrew G. Lee, MD**

Blanton Eye Institute, Houston Methodist Hospital  
Houston, TX

#### Oculoplastics/ Reconstructive Surgery

**Robert Goldberg, MD**

Jules Stein Eye Institute, UCLA  
Los Angeles, CA

**John T. LiVecchi, MD**

University of Central Florida College of Medicine  
Orlando, FL

**Shannath L. Merbs, MD**

Wilmer Eye Institute, Johns Hopkins University  
Baltimore, MD

#### Pediatric Ophthalmology

**Norman B. Medow, MD**

Albert Einstein College of Medicine  
Bronx, NY

**Jennifer Simpson, MD**

University of California, Irvine  
Irvine, CA

**H. Jay Wisnicki, MD**

New York Eye & Ear Infirmiry, Beth Israel Medical Center,  
Albert Einstein College of Medicine  
New York, NY

#### Practice Management

**Joseph C. Noreika, MD**

Medina, OH

**Frank Weinstock, MD**

Boca Raton, FL

#### Refractive Surgery

**William Culbertson, MD**

Bascom Palmer Eye Institute, University of Miami  
Miami, FL

**Peter S. Hersh, MD**

University of Medicine & Dentistry of New Jersey  
Newark, NJ

**Jonathan H. Talamo, MD**

Harvard University  
Boston, MA

**Kazuo Tsubota, MD**

Keio University School of Medicine  
Tokyo, Japan

#### Retina/Vitreous

**Stanley Chang, MD**

Columbia University  
New York, NY

**David Chow, MD**

University of Toronto  
Toronto, Canada

**Pravin U. Dugel, MD**

Phoenix, AZ

**Sharon Fekrat, MD**

Duke University  
Durham, NC

**Julia Haller, MD**

Wills Eye Institute, Thomas Jefferson University  
Philadelphia, PA

**Tarek S. Hassan, MD**

Oakland University  
Rochester, MI

**Michael Ip, MD**

Doheny Eye Institute  
Los Angeles, CA

**Carl D. Regillo, MD**

Wills Eye Institute, Thomas Jefferson University  
Philadelphia, PA

**Lawrence J. Singerman, MD**

Case Western Reserve University  
Cleveland, OH

#### Uveitis

**Emmett T. Cunningham Jr., MD, PhD**

Stanford University  
Stanford, CA

#### Chief Medical Editors-Emeritus

**Jack M. Dodick, MD**

New York University School of Medicine  
New York, NY (1976-1996)

**David R. Guyer, MD**

New York, NY (1996-2004)

### Ophthalmology Times Industry Council

**Leslie Amodi**

Optos Inc., Vice President of Global Product Marketing

**Rahim K. Hirji, RPh**

Omeros Corp., Director - Marketing

**Neil Levine**

Regeneron Healthcare Solutions  
Executive Director, Marketing Ophthalmology

**Cody McKenzie**

Glaukos, Director - U.S. Marketing

**Tom Mitro**

Aerie Pharmaceuticals  
President and Chief Operating Officer

**Brian O'Neal**

Alcon Laboratories Inc., Head of Marketing - U.S. Surgical

**Ram Palanki**

Santen, Senior Vice President of Commercial, Americas

**John Saharek**

Imprimis Pharmaceuticals, Chief Commercial Officer

**Erin Schallhorn**

Carl Zeiss Meditec, Sr. Director, Medical Affairs and  
Professional Education

**Tracy Valorie**

Bausch + Lomb, US Pharmaceuticals and Surgical  
Valeant Pharmaceuticals North America, LLC  
Sr. Vice President and General Manager

### How to Contact Ophthalmology Times

**Editorial**

Millennium Place East  
25115 Country Club Blvd.  
North Olmsted, OH 44070  
440/826-2800, FAX: 440/756-5227

**Subscription Services**

Toll-Free: 888/527-7008 or  
218/740-6477  
FAX: 218/740-6417

**Advertising**

485 Route 1 South  
Building F, Suite 210,  
Iselin, NJ 08830-3009  
732/596-0276, FAX: 732/596-0003

**Production**

131 W. First St.  
Duluth, MN 55802-2065  
800/346-0085  
FAX: 218/740-7223, 218/740-6576

# How retinal surgeons are practicing in 2018

From first-line AMD treatments to video learning, survey reveals wide scope of global trends

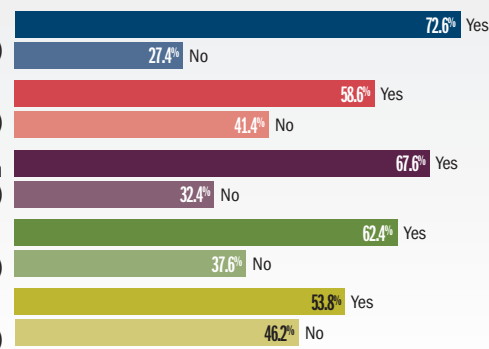
By Michelle Dalton, ELS; Reviewed by Rishi P. Singh, MD

**After how many injections do you consider switching anti-VEGF agents due to inadequate response?**

3-6 injections



**In the past year, have you learned a new technique via online video less than 24 hours before performing it?**



(Figures courtesy of Rishi P. Singh, MD)

From first-line anti-vascular endothelial growth factor (VEGF) for AMD to learning a surgical technique via video, the 2018 global trends in retina survey results are out.

The American Society of Retina Specialists (ASRS) International global trends survey queries 42 international retina societies for leanings and directions of the retina community at large. This year 922 respondents answered questions on medical and surgical retina topics. The results showed many commonalities and regional differences. A total of 15 questions were posed to the international members that were also asked in the annual Preferences and Trends (PAT) Survey.

When it comes to first-line anti-VEGF agents for the treatment of AMD, the overwhelming majority of retina specialists in Africa/Middle East (n = 198) and the United States (n = 740) choose bevacizumab (79.3% and 70.2%, respectively), said Rishi P. Singh, MD, chair of the International Affairs Committee of the ASRS.

First-line choice in the remaining regions of the world (Asia/Pacific [n=223], Central and South America [n = 188], and Europe [n = 298]) is aflibercept, according to results from

the 2018 Global Trends in Retina survey. In those regions where bevacizumab was the first choice, aflibercept was the second choice. In those regions where aflibercept was the first choice, bevacizumab was the second choice with the exception of Central and South America, where ranibizumab was preferred over bevacizumab.

## AMD

Switching therapy in AMD is common. “The majority of us will consider switching anti-VEGF agents due to an inadequate response anywhere from three to six injections,” he said, with percentages ranging from 91.4% in the Africa/Middle East to 78.1% in the United States.

When asked what is the greatest unmet need in neovascular AMD, a desire for long-acting or sustained delivery treatments in neovascular AMD treatment in all regions except the United States and Asia-Pacific. In the US and Asia-Pacific, a reduced treatment burden was considered the greatest unmet need (in 73.2% and 69.1% of respondents, respectively).

Addressing submacular hemorrhage in exudative AMD is a controversial topic. Respondents were asked about treatment recommen-

dations for a submacular hemorrhage due to AMD, where the patient had a visual acuity of 20/200.

In the United States, Central and South America, and Asia/Pacific, anti-VEGF injection therapy was recommended most often (in 54.8%, 54.5%, and 34.5%, respectively). In the Africa/Middle East region, physicians prefer to treat with vitrectomy with tissue plasminogen activator injection (37.1%); in Europe, there was virtually no preference between the two procedures.

## DIABETIC MACULAR EDEMA

Diabetes and diabetic retinopathy is a fast growing worldwide problem. Respondents were asked about the treatment/management of a 30-year-old type 1 diabetic patient with high-risk proliferative diabetic retinopathy, excellent vision (20/20), and no macular edema. Given those parameters, respondents in the Africa/Middle East, Asia/Pacific and European regions would perform a complete pan retinal photocoagulation treatment in two or more sessions (51.8%, 54.3%, and 51.9%, respectively).

In Central and South America, 43.1% of re-

Continues on page 10 : **Retina trends**

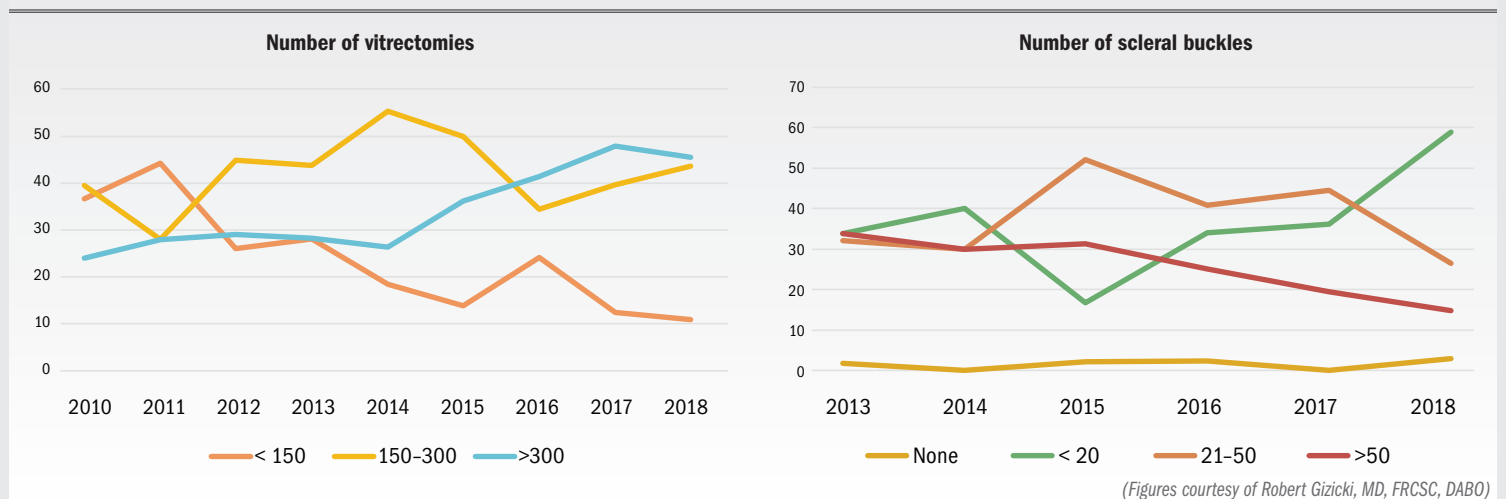


# Fellows report increasing surgical experience during training

However, there is also a trend toward fewer surgeons reporting data, according to survey

By Michelle Dalton, ELS

## Vitreoretinal surgery experience



**AMONG THE EVOLVING** trends in practice patterns of North American vitreoretinal surgery fellows from 2010 to 2018 is that fellows are reporting an increasing number of surgical cases where they are the primary surgeon, said Robert Gizicki, MD, FRCSC, DABO, of the University of Toronto.

However, there is also a trend toward fewer fellows reporting data, he said.

Dr. Gizicki said this survey is distributed to vitreoretinal fellows in their second year of training as part of the ASRS Fellows Forum meeting. The objectives of the meeting itself are numerous: to provide an intensive review of current vitreoretinal treatments, to allow fellows to meet and interact with peers, to encourage research, and to introduce fellows to industry.

The Annual Fellows Forum Survey is approximately 150 questions covering practice patterns in management of age-related macular degeneration (AMD), diabetic retinopathy (DR), retinopathy of prematurity (ROP), vitreoretinal interface disease, retinal detachment, vitreoretinal surgery, and future practice plans.

“This survey provides the basis for educational discussions during the overall meeting,” Dr. Gizicki explained.

From 2010 to 2018 there has been a decline

in the number of respondents, from a high of 89 fellows in 2010 to 71 in 2018. Fellowship length, structure, supervising mentors, and practice settings remained virtually unchanged.

### DIAGNOSTIC MODALITIES

Overall, the use of diagnostic modalities has steadily increased, with about 80% of fellows gaining experience with the technologies in 2018. When fellows were asked whether optical coherence tomography angiography (OCT-A) could replace intravitreal fluorescein angiography, the overwhelming majority do not believe so, with about 75% responding ‘no’ in 2018 and about 78% responding ‘no’ in 2017.

However, a growing number of fellows did think OCT-A would replace FA in macular telangiectasia (22% and 21% in 2017 and 2018, respectively) and neovascular age-related macular degeneration (18% and 22% in 2017 and 2018, respectively).

The initial drug choice for treatment of subfoveal choroidal neovascularization membrane secondary to AMD has consistently remained bevacizumab, but there is a clear increasing use of aflibercept with a correlating decrease in the use of ranibizumab, Dr. Gizicki said.

Monthly and PRN dosing have decreased, while treat and extend has increased.

By 2012, anti-vascular endothelial growth factor (VEGF) had become the treatment of choice as an initial approach for central diabetic macular edema (DME), and by 2017 almost 100% of fellows were using anti-VEGFs for initial treatment.

Most fellows are routinely using anti-VEGFs before recommending vitrectomy for proliferative DR, and most fellows use a bimanual technique during pars plana vitrectomy for tractional retinal detachment.

Regarding ROP, fellows have not varied responses much over the course of the study: about half have done screening in fellowship (about 58% in 2018), and Dr. Gizicki said it is likely once in practice there would be more screening.

About half the fellows have had exposure to surgical training for ROP, and about 60% have had experience performing laser or cryotherapy for ROP. However, about 40% of fellows do not plan to manage ROP after fellowship.

### SURGICAL EXPERIENCE

Fellows are increasing their surgical experience, Dr. Gizicki said.

“Management of retinal detachment increasingly involves vitrectomy and with pneumatic

Continues on page 10 : Experience

## EXPERIENCE

(Continued from page 9)

retinopexy or scleral buckling in select cases," he said. By 2018, about 60% of fellows also had performed 20 or fewer scleral buckle procedures, but the number of fellows who had performed more than 50 scleral buckle procedures decreased from about 33% in 2013 to about 15% by 2018.

Retinal detachment management has also remained fairly stable between 2010 and 2018, with a slight decrease from 60% to 50% of fellows using pneumatic retinoplexy to treat phakic patients with macula on superior retinal detachment with adjacent tears, but primary vitrectomy increased to about 20% for the same condition in 2018.

By 2018, about 70% of fellows would use

primary vitrectomy in a pseudophakic patient with macula on superior retinal detachment with two adjacent tears (pneumatic retinoplexy would be used by about 30% of fellows, which has remained fairly stable over the course of the survey.

### JOB SEARCH

### POST-FELLOWSHIP

When looking for employment post-fellowship, location and partner personalities were the most important factors for fellows, Dr. Gizicki said.

"Starting salary, the ability to do research, and the ability to do high volume surgery were less important, which has not changed from 2010," he said.

The majority of fellows (60%) are heading to private practice, which is a sharp increase from 2010, where fewer than 30% of fellows went into private practice.

There was a decrease in the percentage of fellows opting to work at academic institu-

tions (<10%) in 2018, after a high of almost 40% in 2014.

Starting salaries have slowly increased, with just over 50% of fellows reporting a starting salary of more than \$225,000 in 2018 (compared to about 45% in 2010), with fewer than 10% of fellows reporting a starting salary of \$175,000 or less (compared to just over 10% reporting that salary in 2010). ■

#### ROBERT GIZICKI, MD, FRCSC, DABO

P: 604/521-4144

This article was adapted from Dr. Gizicki's presentation at the 2018 meeting of the American Society of Retina Specialists. He did not indicate any proprietary interest in the subject matter.

## RETINA TRENDS

(Continued from page 8)

spondents prefer an anti-VEGF in conjunction with PRP treatment in two or more sessions. In the United States, there was no clear preference between those two treatment options.

The release of Protocol U from the Diabetic Retinopathy Clinical Research Network's evaluated the efficacy of the dexamethasone implant in combination with anti-VEGF for the treatment of persistent DME. In Protocol U, top-line results at month 6 showed no significant difference in VA outcomes between the two treatment arms, with mean improvements of 2.7 letters in the combination arm and 3 letters in the monotherapy arm.

There was, however, a significantly greater reduction in retinal thickness in the combination group, with mean central subfield thickness decreases of 110  $\mu$ m with combination therapy compared with 62  $\mu$ m with monotherapy.

In the Global Trends Survey, more respondents in the Africa and Middle East, Asia/Pacific, and United States were unlikely to alter their management, while respondents in Central and South America and Europe were more likely to continue anti-VEGF injections prior to switching to a corticosteroid. In each region, fewer than 30% of respondents would choose to switch to a corticosteroid earlier over continuing anti-VEGF injections.

### RETINAL VEIN OCCLUSION

For patients with mildly symptomatic central retinal vein occlusion, minimal thickening on OCT, and very good vision (20/25), most regions responded they would either observe or defer treatment until the macular edema or vision worsened. However, in the Africa/Middle East region, 48.4% of respondents would immediately initiate anti-VEGF therapy, "as most eyes will worsen," Dr. Singh said.

### SURGICAL DEVICES

With the exception of U.S.-based respondents, most surgeons have not yet used 3-D heads-up visualization systems, but for those who have used it, more find it useful than not. In the United States, 36.3% of the respondents have used the device and found it helpful, he said.

Only 17.8% of U.S. respondents said they had used the device in the operating room but did not find it helpful.

The majority of respondents in all regions have not yet tried intraoperative OCT. However, when respondents had tried it, opinions were split about its usefulness, Dr. Singh said.

For instance, in the Africa and Middle East region, 17.9% of respondents did not find it useful for macular surgery compared with 1.7% who did find it useful. In the Asia/Pacific region, 8.6% found it useful for macular surgery compared to 6.1% who did not. In Central and South America, 3.4% found it useful for macular surgery compared to 5.7% who did not. In Europe, 10.7% found it useful for macular surgery compared to 9.1% who did not. In the

United States, 4.4% found it useful for macular surgery compared to 8.0% who did not.

Few surgeons have tried "no face-down" positioning after macular hole surgery, and small percentages of respondents indicated they had tried it and now incorporate it into their practice (13.3% in Africa/Middle East, 9.7% in Asia/Pacific, 17.5% in Central and South America, 16.9% in Europe, and 13.1% in the United States).

Most surgeons will learn a new surgical technique via an online video less than 24 hours before first performing it, he noted.

"I do this all the time," Dr. Singh said, acknowledging that in the United States, the percentages were closer than they were in any other region (with 53.8% of respondents using online video and 46.2% who do not).

Pneumatic retinopexy is not commonly performed, with the majority of respondents in each region noting they perform the procedure less than once a month. In Europe, there was almost the same percentage of respondents who perform pneumatic retinopexy less than once a month (44.1%) as the percentage of those who never perform it (41.3%). In the United States, 26.2% of respondents perform the procedure 1-3 times a month. ■

#### RISHI P. SINGH, MD

E: drishisingh@gmail.com

This article was adapted from Dr. Singh's presentation at the 2018 meeting of the American Society of Retina Specialists. He did not indicate any proprietary interest in the subject matter.

# Tips for treating patients with conjunctival chalasis

Surgery offers a step toward healing, provides symptomatic relief

By **Neel R. Desai, MD**; Special to Ophthalmology Times

**A**mong the mechanical problems related to dry eye is conjunctivochalasis (or conjunctival chalasis)—the Tenon's capsule condition in which long-term chronic inflammation and dry eye causes dissolution of normal Tenon's fascia.

The conjunctiva becomes loose (not redundant), shortening the inferior fornix tear reservoir, where half the tear volume resides in healthy eyes. No amount of medication, supplements, or warm compresses will alleviate dry eye in the presence of this mechanical challenge.

I follow a two-pronged approach to the problem.

First, I surgically reconstruct the inferior fornix and tear reservoir.

Second, I start long-term therapy to control inflammation and dry eye disease. The re-

sult is relief from dry eye symptoms, including reduced inflammation that prevents conjunctivochalasis from re-occurring.

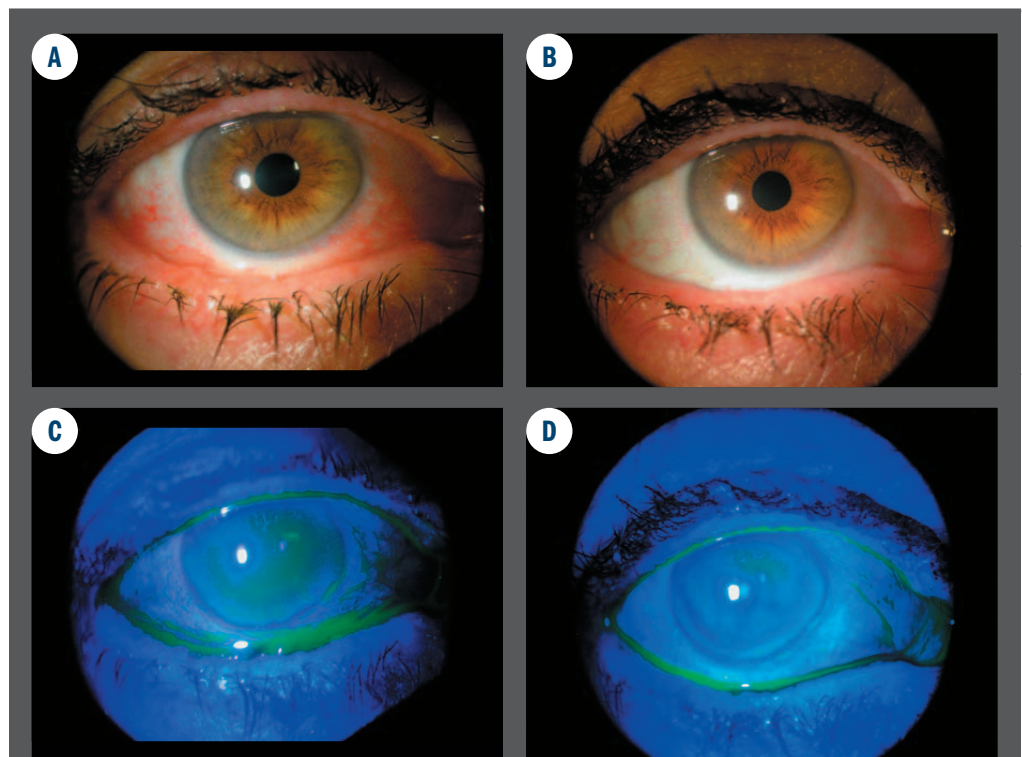
## DIAGNOSING CONJUNCTIVOCHALASIS

When we see patients who have had dry eye disease for many years, it is wise to consider mechanical deficiencies. They may have the biochemical etiology for dry eye disease, and this mechano-anatomical issue is a long-term consequence.

Diagnosis begins with a detailed history, including symptoms such as epiphora and foreign body sensation that is not relieved by artificial tears because the patient has no natural reservoir to retain them. In the slit lamp exam, I

### TAKE-HOME

► **Neel R. Desai, MD, treats conjunctivochalasis through surgically reconstructing the inferior fornix and tear reservoir, combined with long-term therapy to control inflammation.**



(FIGURE 1) Conjunctivochalasis (CCh) often coincides with ocular surface inflammation and lid margin disease. **A.** As foreshortening of the tear reservoir results in erosive loss of lid margin architecture. Dissolution of Tenon's fascia in CCh results in loose conjunctiva that billows over the lid margin and interrupts the normal tear meniscus **B.** producing the pathognomonic "Morse-code Meniscus" sign. Following Reservoir Restoration surgery for CCh using cryopreserved amniotic membrane, the ocular surface and lid margin demonstrate regenerative healing with reduction in inflammatory signs **C.** and restoration of the tear meniscus and reservoir **D.** (Photos courtesy of Neel R. Desai, MD)

well as how testing and history tell us which treatment is best to target each patient's type of dry eye.

### EFFECTIVE SURGICAL REPAIR

The only way to treat conjunctivochalasis is to reconstruct the inferior fornix and restore the normal anatomy.

Unfortunately, as a result of poor nomenclature, some surgeons choose repair procedures that exacerbate the problem.

The term conjunctivochalasis falsely suggests that the patients have excess conjunctiva, so it is pinched and snipped or cauterized,

otic membrane, which forms an effective platform for conjunctival growth. The procedure takes about 10 to 15 minutes and is covered by insurance using codes for ocular surface reconstruction with multilayer graft, and conjunctivoplasty with extensive rearrangement of the conjunctiva and reconstruction of the cul-de-sac.

By smoothing out the conjunctiva and restoring the anatomy of the inferior fornix, we are able to use standard therapies for dry eye with greater beneficial effect, thus addressing both the anatomical and biochemical facets

*Continues on page 12 : Dry eye relief*

## DRY EYE RELIEF

(Continued from page 11)

of the patient's problem. By the time patients present with conjunctivochalasis, they have experienced advanced dry eye disease for years.

In addition to judging that surgery is the best treatment, I also like that a procedure covered by insurance offers a significant initial step toward healing and symptomatic relief.

Once my patients experience symptomatic improvement after surgery, I perform a combination of intense pulsed light (IPL) therapy (M22 OPT, Lumenis) to reduce inflammatory mediators from capillaries on the eyelids and around the eyes and thermal pulsation therapy (LipiFlow, Johnson & Johnson Vision) to clear the meibomian glands and help them function effectively again.

Thermal pulsation is a single treatment, although patients can be re-treated a year later if needed. Patients typically have four IPL ses-

sions two to four weeks apart, with maintenance treatment four to six months later and again after increasingly longer intervals (eventually reaching once per year).

I often prescribe cyclosporine (Restasis, Allergan) or lifitegrast (Xiidra, Shire), and patients continue re-esterified omega-3 fatty acid supplements (HydroEye, ScienceBased Health). I encourage patients to continue using hot compresses as well.

By continuing long-term care and therapy for dry eye, patients not only achieve the symptomatic relief they want, but also, in turn, prevent a return of conjunctivochalasis. ■



**NEEL R. DESAI, MD**

P: 727/518-2020

*Dr. Desai is the director of the Cornea, Cataract, and Refractive Services at The Eye Institute of West Florida, medical director of the*

*Lions Eye Institute for Transplant Research, and president and CEO of Clarity Visionary Consulting. Dr. Desai is a consultant to Allergan, BioTissue, Lumenis, Johnson & Johnson Vision, and Shire.*

**OT** OphthalmologyTimes.com  
Online Exclusive

### 5 STRATEGIC WAYS TO CARE FOR OLDER PATIENTS WITH ADVANCED DRY EYE

**MANY OLDER PATIENTS ARE TOLD** their dry, red eyes are a part of aging, like aching knees or gray hair. It's true—patients over 60 are more likely to have dry eye than people under 30, but, like aching knees and gray hair, dry eye is treatable, says Neel R. Desai, MD.

When these patients enter our practices, feeling uncomfortable and frustrated, unable to do the activities they love, and often repeatedly brushed off by other doctors, we need to convey they've finally come to the right place, he says.

Go to [OphthalmologyTimes.com/AdvancedDryEye](http://OphthalmologyTimes.com/AdvancedDryEye)

## Study suggests possible association with education, risk of myopia

**THE MORE EDUCATED** a person is, the more myopic he or she is likely to become, according to researchers at the University of Bristol, UK.

Studies have linked education with myopia for more than a century, but until now, researchers have not been able to shed light on whether one causes the other or if a third factor is responsible.

Prospective trials have shown that time spent outdoors reduces the risk of myopia. Weaker evidence has associated close work with myopia. But researchers have not previously been able to elucidate how education fits into this equation.

For example, they have not been able to rule out the hypotheses that being myopic stimulates people to spend more time studying, or that a factor such as intelligence or higher socioeconomic status could both cause myopia and lead people to spend more time studying.

The best way to establish cause and effect is a randomized, controlled trial. But it would be unethical to assign one group of children to receive more education than another.

So the Bristol researchers turned to Mendelian randomization.

In this approach, they used random aspects

of the subjects' genomes as proxies for the kind of randomisation that would have been done in a controlled trial.

They drew their data from a large population cohort, known as the UK Biobank, examining cross sectional data from the UK Biobank collected between 2006 and 2010. UK Biobank recruited 502,664 participants aged 40 to 69 years through 22 assessment centers across the UK.

To determine the genotype of participants, one of two platforms was used: the BiLEVE Axiom array (Affymetrix) or the Biobank Axiom array (Affymetrix). The participants completed sociodemographic questionnaires, including questions on past educational and professional qualifications. About 23% of participants also completed an ophthalmic assessment.

For every additional year spent in education, the researchers found an increase in myopic refractive error of 0.27 D. This suggests that a UK university graduate with 17 years in education would, on average, be one diopter more myopic than an individual who left school at 16 with 12 years of education. This difference in myopia severity is enough to blur vision for driving below legal standards.

"Our study provides strong evidence that

length of time spent in education is a causal risk factor for myopia," said Dr. Atan. "Axial eye growth happens mainly during school years and since levels of myopia tend to even out in adulthood, any interventions to stop or prevent myopia need to be given in childhood."

He added: "Policymakers should be aware that the educational practices used to teach children, and to promote personal and economic health, may have the unintended consequence of causing increasing levels of myopia and later visual disability as a result."

The study could not determine exactly how education impacts eyesight, but previous studies provide some hypotheses.

Children from developed East and Southeast Asian countries regularly say that they spend less time outdoors than children from Australia or the U.S., where the prevalence of myopia is lower.

Other research has associated higher light exposure with lower myopia risk, and it is possible that individuals who spend more time in education have less exposure to natural light.

Myopia is one of the leading causes of visual disability in the world. The global prevalence has reached epidemic levels in the developed countries of East and Southeast Asia. ■

# Improving clinical outcomes for patients with dense cataracts

OCT-based biometers are making more accurate axial measurements possible

By Akeno Tamaoki, CO; Noemi Misuraca, OA; and Carmela Palmisano, MD, FEBOphth

**REFRACTIVE CATARACT** surgery has advanced at a monumental pace, bringing high patient expectations,<sup>1</sup> more frequent<sup>2,3</sup> procedures and higher disease severity.

Even with advanced IOLs and techniques, optimal clinical outcomes for patients depend largely on precision planning, which is facilitated by ocular biometer devices.

These instruments provide surgeons with valuable biometry and keratometry parameters that can be plugged into formulae for accurately calculating IOL power. Pinpoint measurements have been shown to be essential for postoperative visual acuity, with even minor errors translating to notable postoperative refractive error.<sup>4</sup>

## CURRENT BIOMETRIC PARADIGM

Multiple options for performing biometric measurements are available, with varying technical modalities for determining the spectrum of essential parameters.

For example, the IOLMaster 500 (Carl Zeiss Meditec) utilizes partial coherence interferometry via a 780-nm infrared laser diode and lateral slit illumination for measuring anterior chamber parameters. Another instrument, the Lenstar LS900 (Haag-Streit) employs optical low-coherence reflectometry via an 820-nm superluminescent diode to measure all axial parameters.

Although the precision of these older devices is well established in the literature, they fall short in performing axial calculations in more severely cataractous lenses. Both dense nuclear and posterior subcapsular cataracts are prone to light scattering, resulting in significant signal attenuation from the retina.

## THE NEXT WAVE OF BIOMETRY

New biometers have been developed in an attempt to better serve patients with severe cases of cataractous disease. We now have several years of experience with one such biometer,

the ARGOS (Movu Inc.). Unlike older technology, this device utilizes a 1,060-nm wavelength and 20-nm swept-source technology to perform two-dimensional, full-eye optical coherence tomography (OCT).

This allows for comprehensive measurement of standard axial parameters, central corneal and lens thickness, pupil size, and aqueous humour depth. In addition, a ring LED allows for keratometry.

Furthermore, the device utilizes a safeguard system for patients unable to correctly fixate their vision during collection: a panoramic view of the eye facilitates alignment with the center of the pupil, mitigating initial measurement errors. In addition, the system is designed to alert the user in the case of ongoing misalignment, allowing manual adjustment in particularly difficult cases.

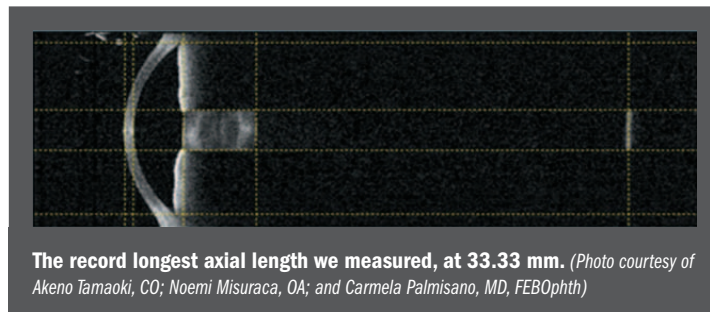
But how does this technology benefit the patients previously mentioned, those with mature, dense, difficult-to-measure cataracts? In our experience the ARGOS far surpasses current modalities in measuring axial length in eyes with dense cataracts.

We have successfully performed measurements in many cases that would have been impossible with older devices. Our experience includes successful and accurate measurements in patients with significant posterior subcapsular changes, late-stage cortical changes and the highest severity of nuclear sclerosis.

With this biometer, axial length is truer to the absolute distance, as two-dimensional full-eye imaging allows for inclusion of characteristics that affect axial length but were previously unaccounted for, such as lens thickness. The device also uses the appropriate refractive index (based on research and consensus) for the respective ocular elements, eliminating

the need for nomograms that “correct” the axial length for significantly short or long eyes.

Additionally, the OCT employs a wide-scanning beam able to travel beyond the region of the cataract, so that retinal signals are no longer attenuated. The increased wavelength facilitates deeper penetration of the cataract,



removing a lot of the guesswork that went into determining accurate IOL power calculations for these patients.

With this technology, we have personally measured axial length as long as 33.33 mm. ■

## TAKE-HOME

► **OCT-based biometers like the ARGOS allow for accurate measurement of very dense lenses in cataractous patients.**

OT

To read the fully referenced article online, go to [bit.ly/20yuhUI](http://bit.ly/20yuhUI)

### AKENO TAMAOKI, CO

Dr. Tamaoki is based at Chukyo Hospital in Nagoya, Japan. Dr. Tamaoki reports no financial interests in the subject matter.

### CARMELA PALMISANO, MD, FEBOPHTH

E: [abigail@santec.com](mailto:abigail@santec.com)

Dr. Palmisano is based at the University of Bari Hospital in Bari, Italy and reports no financial disclosures.

### NOEMI MISURACA, OA

E: [noemimisuraca@pec.it](mailto:noemimisuraca@pec.it)

Dr. Misuraca is based at the University of Bari Hospital in Bari, Italy. Dr. Misuraca has no financial disclosures to make.

# Use optic stereo-photography in conjunction with OCT

New device appears to overcome obstacles of image acquisition in traditional photography

By Francesco Oddone, MD, PhD

**G**laucoma is major global health problem<sup>1</sup>—the World Health Organization reports it is the second-largest cause of permanent blindness worldwide; various authors estimate that the disease causes 2.1 to 4.4 million such cases worldwide,<sup>2,3</sup> and a retrospective series found that blindness occurred in about 20% of glaucoma patients.<sup>4</sup>

Glaucoma is a degenerative disease characterized by typical morphological changes in the optic nerve head (ONH) and the retinal nerve fiber layer (RNFL), followed by a corresponding loss of the visual field (VF), having a major impact on the quality of life of patients.<sup>5,6</sup>

The complex nature of glaucoma requires a comprehensive assessment of each patient, including measurement of IOP, and ONH and VF evaluation, which are critical steps in the diagnosis and monitoring of the disease.

## OPTIC NERVE HEAD ASSESSMENT

The detection of structural damage to the ONH is central to the diagnosis of glaucoma and is extremely important for monitoring both patients at risk and those with established disease. Glaucoma, by definition, is an optic neuropathy and, therefore, particular attention must be given to examination of the optic nerve.

The ONH is the site at which the dropout of retinal ganglion cells is identified most easily using current clinical techniques and is postulated as the primary site for damage.<sup>7,8</sup>

Traditionally, the assessment of ONH health is performed by stereoscopic photographs, a technique that improves the detection of RNFL and optic disc changes, including optic disc hemorrhages (ODHs) that would not be

evident on ophthalmoscopy or monoscopic photographs.

The Ocular Hypertension Treatment Study compared stereoscopic photographs with clinical examination in 1,618 participants (3,236 eyes) who were followed for 96.3 months. The photographs enabled the detection of ODHs in 128 eyes of 123 participants.

Twenty-one cases (16%) were detected by both clinical examination and review of photographs, and 107 cases (84%) were detected only by review of photographs ( $p < 0.0001$ ).<sup>10</sup>

Regarding the monoscopic photograph of the retina, the lack of stereopsis could lead the operator to assess the clinical situation on the basis of the colour of the area rather than the contour of the neuroretinal rim,<sup>9,11</sup> but the stereoscopic photography provided higher levels of interobserver agreement compared with monoscopic assessments.

Observers reading photographs in the context of major clinical trials are generally reported to have low interobserver variability, while others have reported much greater variability.<sup>12</sup>

Despite its advantages, traditional stereoscopic photography has some limitations. Firstly, the process of capturing the image is not easy, since the cameras are complex and the process is time-consuming.

In addition, the reliability of the image is highly influenced by such factors as the camera angle, photographic technique, lighting and magnification<sup>13</sup> while the experience of the operator evaluating the photographs also has an effect.<sup>14,15</sup>

The above-mentioned constraints of stereoscopic photography have favored the diffusion

of high-tech imaging technologies, such as optical coherence tomography (OCT), which allows fast and reproducible high-resolution

quantitative evaluation of ONH and RNFL with good diagnostic accuracy.<sup>16</sup>

Imaging with OCT, however, also has some inherent drawbacks, such as the lack of qualitative information about the structures being evaluated and the fact that it is a fast-evolving technology affected by early obsolescence, thus limiting the ability to monitor patients over the long term.

## INCREASING THE SCOPE

The stereoscopic photograph—for its reliability, the qualitative nature of the image, and possibility of monitoring patients over the long term—provides relevant information for the assessment of the ONH that warrants being integrated with the data obtained with OCT. However, its aforementioned technical limitations have caused a decline of stereoscopic photography, thus reducing the availability of valuable data for the diagnosis and monitoring of glaucoma.

A new automated perimeter combined with a white light scanning ophthalmoscope, Compass (Centervue), provides confocal images of the retina.

The stereo photograph feature of the device overcomes some of the limitations of traditional stereo photographs, due to the specific techniques used.

The most significant advancement is represented by its process of image acquisition: the first photograph is automatically captured with a focus on the rim; while for the second photograph, the device automatically focuses on the lamina cribrosa.

This double focus enhances its three-dimensional effect and, together with the confocal system and the white light source, enables the capture of high-quality images.

In our experience, we obtained excellent images without the need for pupil dilation—the assessment of ONH was possible even in the presence of media opacities, such as early and mild cataract.

The characteristics of the device define a


*Continues on page 18 : Optic stereo*

## TAKE-HOME

► **Stereoscopic photographs are a useful tool in the detection of glaucoma. However, the difficulty in obtaining images has seen them underused in favor of optical coherence tomography (OCT). A new device is attempting to redress this balance, enabling stereo-photography to be used alongside OCT for optimal practice.**

# “LOTEMAX® GEL: An established formulation designed with your treatment goals in mind”

 **LOTEMAX® GEL**  
loteprednol etabonate  
ophthalmic gel 0.5%



Join expert Marguerite McDonald, MD, FACS in a webinar presentation on LOTE MAX® GEL: Formulation, Clinical Data, and History of the Molecule.

**Watch on-demand now!**

access at [ophthalmologytimes.com/lotemax-webinar](https://ophthalmologytimes.com/lotemax-webinar)

## Indication

LOTE MAX® GEL (loteprednol etabonate ophthalmic gel) 0.5% is indicated for the treatment of post-operative inflammation and pain following ocular surgery.

## Important Safety Information about LOTE MAX® GEL

- LOTE MAX® GEL is contraindicated in most viral diseases of the cornea and conjunctiva including epithelial herpes simplex keratitis (dendritic keratitis), vaccinia, and varicella, and also in mycobacterial infection of the eye and fungal diseases of ocular structures.
- Prolonged use of corticosteroids may result in glaucoma with damage to the optic nerve, defects in visual acuity and fields of vision. If this product is used for 10 days or longer, IOP should be monitored.
- Use of corticosteroids may result in posterior subcapsular cataract formation.
- Use of steroids after cataract surgery may delay healing and increase the incidence of bleb formation and occurrence of perforations in those with diseases causing corneal and scleral thinning. The initial prescription and renewal of the medication order should be made by a physician only after examination of the patient with the aid of magnification, and where appropriate, fluorescein staining.
- Prolonged use of corticosteroids may suppress the host response and thus increase the hazard of secondary ocular infection. In acute purulent conditions, steroids may mask infection or enhance existing infections.
- Use of corticosteroid medication in the treatment of patients with a history of herpes simplex requires great caution. Use of ocular steroids may prolong the course and exacerbate the severity of many viral infections of the eye (including herpes simplex).
- Fungal infections of the cornea are particularly prone to develop coincidentally with long-term local steroid application. Fungus invasion must be considered in any persistent corneal ulceration where a steroid has been used or is in use.
- Patients should not wear contact lenses when using LOTE MAX® GEL
- The most common ocular adverse drug reactions were anterior chamber inflammation (5%), eye pain (2%) and foreign body sensation (2%).

**Please see brief summary of Prescribing Information on adjacent page.**

This resource is brought to you by *Ophthalmology Times* and sponsored by Bausch + Lomb. It may contain promotional material.

LOTE MAX is a trademark of Bausch & Lomb Incorporated or its affiliates.

©Bausch & Lomb Incorporated. All rights reserved. Printed in USA. LGX.0112.USA.17

**BAUSCH + LOMB**

## BRIEF SUMMARY OF PRESCRIBING INFORMATION

This Brief Summary does not include all the information needed to prescribe Lotemax Gel safely and effectively. See full prescribing information for Lotemax Gel.

## Lotemax (loteprednol etabonate ophthalmic gel) 0.5%

Rx only

Initial Rx Approval: 1998

### INDICATIONS AND USAGE

LOTEMAX is a corticosteroid indicated for the treatment of post-operative inflammation and pain following ocular surgery.

### DOSAGE AND ADMINISTRATION

Invert closed bottle and shake once to fill tip before instilling drops.

Apply one to two drops of LOTE MAX into the conjunctival sac of the affected eye four times daily beginning the day after surgery and continuing throughout the first 2 weeks of the post-operative period.

### CONTRAINDICATIONS

LOTEMAX, as with other ophthalmic corticosteroids, is contraindicated in most viral diseases of the cornea and conjunctiva including epithelial herpes simplex keratitis (dendritic keratitis), vaccinia, and varicella, and also in mycobacterial infection of the eye and fungal diseases of ocular structures.

### WARNINGS AND PRECAUTIONS

#### Intraocular Pressure (IOP) Increase

Prolonged use of corticosteroids may result in glaucoma with damage to the optic nerve, defects in visual acuity and fields of vision. Steroids should be used with caution in the presence of glaucoma. If this product is used for 10 days or longer, intraocular pressure should be monitored.

#### Cataracts

Use of corticosteroids may result in posterior subcapsular cataract formation.

#### Delayed Healing

The use of steroids after cataract surgery may delay healing and increase the incidence of bleb formation. In those diseases causing thinning of the cornea or sclera, perforations have been known to occur with the use of topical steroids. The initial prescription and renewal of the medication order should be made by a physician only after examination of the patient with the aid of magnification such as slit lamp biomicroscopy and, where appropriate, fluorescein staining.

#### Bacterial Infections

Prolonged use of corticosteroids may suppress the host response and thus increase the hazard of secondary ocular infections. In acute purulent conditions of the eye, steroids may mask infection or enhance existing infection.

#### Viral Infections

Employment of a corticosteroid medication in the treatment of patients with a history of herpes simplex requires great caution. Use of ocular steroids may prolong the course and may exacerbate the severity of many viral infections of the eye (including herpes simplex).

#### Fungal Infections

Fungal infections of the cornea are particularly prone to develop coincidentally with long-term local steroid application. Fungus invasion must be considered in any persistent corneal ulceration where a steroid has been used or is in use. Fungal cultures should be taken when appropriate.

#### Contact Lens Wear

Patients should not wear contact lenses during their course of therapy with LOTE MAX.

### ADVERSE REACTIONS

Adverse reactions associated with ophthalmic steroids include elevated intraocular pressure, which may be associated with infrequent optic nerve damage, visual acuity and field defects, posterior subcapsular cataract formation, delayed wound healing and secondary ocular infection from pathogens including herpes simplex, and perforation of the globe where there is thinning of the cornea or sclera.

The most common adverse drug reactions reported were anterior chamber inflammation (5%), eye pain (2%), and foreign body sensation (2%).

### USE IN SPECIFIC POPULATIONS

#### Pregnancy

#### Teratogenic Effects

Loteprednol etabonate has been shown to be embryotoxic (delayed

ossification) and teratogenic (increased incidence of meningocele, abnormal left common carotid artery, and limb flexures) when administered orally to rabbits during organogenesis at a dose of 3 mg/kg/day (35 times the maximum daily clinical dose), a dose which caused no maternal toxicity. The no-observed-effect-level (NOEL) for these effects was 0.5 mg/kg/day (6 times the maximum daily clinical dose). Oral treatment of rats during organogenesis resulted in teratogenicity (absent innominate artery at  $\geq 5$  mg/kg/day doses, and cleft palate and umbilical hernia at  $\geq 50$  mg/kg/day) and embryotoxicity (increased post-implantation losses at 100 mg/kg/day and decreased fetal body weight and skeletal ossification with  $\geq 50$  mg/kg/day). Treatment of rats with 0.5 mg/kg/day (6 times the maximum clinical dose) during organogenesis did not result in any reproductive toxicity. Loteprednol etabonate was maternally toxic (significantly reduced body weight gain during treatment) when administered to pregnant rats during organogenesis at doses of  $\geq 5$  mg/kg/day.

Oral exposure of female rats to 50 mg/kg/day of loteprednol etabonate from the start of the fetal period through the end of lactation, a maternally toxic treatment regimen (significantly decreased body weight gain), gave rise to decreased growth and survival, and retarded development in the offspring during lactation; the NOEL for these effects was 5 mg/kg/day. Loteprednol etabonate had no effect on the duration of gestation or parturition when administered orally to pregnant rats at doses up to 50 mg/kg/day during the fetal period.

There are no adequate and well controlled studies in pregnant women. LOTE MAX should be used during pregnancy only if the potential benefit justifies the potential risk to the fetus.

#### Nursing Mothers

It is not known whether topical ophthalmic administration of corticosteroids could result in sufficient systemic absorption to produce detectable quantities in human milk. Systemic steroids appear in human milk and could suppress growth, interfere with endogenous corticosteroid production, or cause other untoward effects. Caution should be exercised when LOTE MAX is administered to a nursing woman.

#### Pediatric Use

Safety and effectiveness in pediatric patients have not been established.

#### Geriatric Use

No overall differences in safety and effectiveness have been observed between elderly and younger patients.

### NONCLINICAL TOXICOLOGY

#### Carcinogenesis, Mutagenesis, Impairment Of Fertility

Long-term animal studies have not been conducted to evaluate the carcinogenic potential of loteprednol etabonate. Loteprednol etabonate was not genotoxic *in vitro* in the Ames test, the mouse lymphoma tk assay, or in a chromosome aberration test in human lymphocytes, or *in vivo* in the single dose mouse micronucleus assay. Treatment of male and female rats with up to 50 mg/kg/day and 25 mg/kg/day of loteprednol etabonate, respectively, (600 and 300 times the maximum clinical dose, respectively) prior to and during mating did not impair fertility in either gender.

### PATIENT COUNSELING INFORMATION

#### Administration

Invert closed bottle and shake once to fill tip before instilling drops.

#### Risk of Contamination

Patients should be advised not to allow the dropper tip to touch any surface, as this may contaminate the gel.

#### Contact Lens Wear

Patients should be advised not to wear contact lenses when using LOTE MAX.

#### Risk of Secondary Infection

If pain develops, redness, itching or inflammation becomes aggravated, the patient should be advised to consult a physician.

Bausch + Lomb, a division of Valeant Pharmaceuticals North America LLC  
Bridgewater, NJ 08807 USA

US Patent No. 5,800,807

©Bausch & Lomb Incorporated

Lotemax is a registered trademark of Bausch & Lomb Incorporated or its affiliates.

LGX.0114.USA.16

Based on 9269101/9269201

Revised: 08/2016



# What updated ICO guidelines mean for patients' diabetic eye care

New guidelines include caring for the treatment of DME in developing countries

By Vanessa Caceres

**WITH THE PROLIFERATION** of diabetes around the globe, ophthalmologists located in countries that are treating diabetic retinopathy and diabetic macular edema (DME) more often now are in need of detailed guidelines to assist them.

This is what led a team of eye-care providers to update the International Council of Ophthalmology's (ICO) Guidelines for Diabetic Eye Care. The original guidelines were released in 2013. Yet in the couple of years since those guidelines were published, there have been changes that warranted an update, said Tien Yin Wong, MD, PhD, medical director, Singapore National Eye Centre, and academic chair, Ophthalmology and Visual Sciences Program, Duke-NUS Medical School, National University of Singapore, Singapore. Dr. Wong is chairman of the 2016 Diabetic Eye Care Committee that updated the guidelines.

"The ICO felt the need for a revised set of guidelines," Dr. Wong said. "First, there's the changing epidemiology of diabetes affecting many countries outside of the Western world, but there are no guidelines for many of these developing countries with lower resources than in the Western developed countries with more resources and more ophthalmologists.

"Second, there is emerging eye technology, such as cost-effective screening digital retinal cameras," Dr. Wong said. "Third, there's the changing treatment for DME and proliferative diabetic retinopathy with the widespread use of anti-vascular endothelial growth factor [VEGF] therapy. How it should be used in different countries with different levels of resource settings is not clear."

That's where the guidelines come into the picture. The 40-page document (available at <http://www.icoph.org/downloads/ICOGuidelines-forDiabeticEyeCare.pdf>) addresses screening, referral, follow-up, and treatment for diabetic retinopathy and DME. However, it also stratifies its recommendations according to high-resource settings (such as the United States) and intermediate- and low-resource settings. The document includes pictures to show how various forms and signs of diabetic retinopathy and DME appear.

## Highlights from the Table of Contents for ICO's Guidelines for Diabetic Eye Care

### INTRODUCTION

Epidemiology of Diabetic Retinopathy  
Classification of Diabetic Retinopathy  
Nonproliferative Diabetic Retinopathy  
Proliferative Diabetic Retinopathy  
Diabetic Macular Edema (DME)

### SCREENING GUIDELINES

Referral Guidelines Detailed Ophthalmic Assessment of Diabetic Retinopathy

### INITIAL PATIENT ASSESSMENT

Patient History (Key Elements)  
Initial Physical Exam (Key Elements)  
Fundus Examination Assessment Methods  
Follow-up Examination of Patients with Diabetic Retinopathy  
Follow-up History  
Follow-up Physical Exam  
Ancillary Tests (High Resource Settings)  
Patient Education

### TREATMENT OF DIABETIC RETINOPATHY

High Resource Settings  
Low-/Intermediate Resource Settings  
Panretinal Photocoagulation (PRP)  
Pre-treatment Discussion with Patients  
Lenses for PRP

### TREATMENT FOR DIABETIC MACULAR EDEMA (DME)

High Resource Settings  
Low-/Intermediate Resource Settings  
Laser Technique for Macular Edema  
Modified-ETDRS and the Mild Macular Grid Laser  
Photocoagulation Techniques

### INDICATIONS FOR VITRECTOMY

### MANAGEMENT OF DIABETIC RETINOPATHY IN SPECIAL CIRCUMSTANCES

Pregnancy  
Cataract

### LIST OF SUGGESTED INDICATORS FOR EVALUATION OF DR PROGRAMS Equipment

### **GUIDELINE CHANGES**

Compared with its original publication, the guidelines provide some updates and new information.

"There is increased recognition of the value of routine, universal screening for diabetic retinopathy among all persons with diabetes," Dr. Wong said. "This has been clearly demonstrated in the UK. There is also increased use of new technology such as OCT for diagnosis and screening of diabetic retinopathy."

The mainstream use of anti-VEGF therapy even in many low-resource countries also led to some of the guideline revisions.

Another area addressed by the updated ICO

guidelines is whether a pregnant woman with diabetic retinopathy should undergo a vaginal delivery, said retinal specialist Srilaxmi Bearely, MD, MHS, assistant professor of ophthalmology, Columbia University Medical Center, New York.

"The ICO guidelines specifically state that the presence of diabetic retinopathy by itself, 'should not be considered a contraindication to vaginal birth,'" she said.

The updated guidelines also now address the presence of concurrent diabetic retinopathy and cataract surgery. Specifically, they advise that a patient with a mild cataract but with-

*Continues on page 18 : ICO guidelines*

## ICO GUIDELINES

(Continued from page 17)

out vision loss and with a clear fundus view may not require cataract surgery. If there is a moderate cataract, physicians should carefully assess diabetic retinopathy status and attempt to treat any severe nonproliferative diabetic retinopathy with laser pan-retinal photocoagulation and/or DME with focal/grid laser or anti-VEGF therapy before cataract surgery.

“Once DR/DME is stable, consider cataract surgery to improve vision,” the guidelines advise.

In a patient with diabetic retinopathy and severe to advanced cataract with a poor fundus view, consider early cataract surgery followed by assessment and treatment as necessary.

“If DME is present, consider anti-VEGF before surgery, at the time of surgery, or after surgery if DME is discovered when the media is cleared,” the guidelines recommend.

### A BROADER CONTEXT

The updated information from the ICO can potentially help surgeons in all settings worldwide.

The guidelines “give countries who do not have the necessary history or tradition of treat-

ing diabetic retinopathy the foundation of what is the ‘basic’ care model of diabetes: screening, appropriate and timely referral, and what constitutes the basic examination, and what constitutes adequate treatment,” Dr. Wong said. “Many countries cannot depend on large-scale randomized trials done in the U.S. or Europe to guide their care of diabetic patients.”

However, ophthalmologists abroad are not the only ones who might refer to the guidelines, Dr. Bearely said.

“While there are not new recommendations for U.S. retinal specialists, it should be recognized that there are many segments of our U.S. population that have poor health awareness and inadequate access to care, particularly in rural areas,” Dr. Bearely said. “Even though we are able to prevent 98% of blindness from diabetes with our current treatments, only

about 50% of those with diabetes get screening. The ICO guidelines allow for telemedicine approaches to diabetic retinopathy screening.”

Typically, retinal specialists in the United States use information from large randomized

trials, such as those performed by DRCR.net—the Diabetic Retinopathy Clinical Research Network—to help guide care, Dr. Bearely said.

However, the ICO guidelines take into ac-

‘Many countries cannot depend on large-scale randomized trials done in the U.S. or Europe to guide the care of their diabetic patients.’

count both randomized trials and experience from real-world experience in various settings, she explained.

One other area the guidelines can assist with is expanding the scope of care beyond just eye doctors.

“The diabetes epidemic is larger than the eye-care community is capable of addressing,” Dr. Bearely said. “Screening, referral, and follow-up guidelines such as these help to involve physicians and other health care providers with evidence-based management principles.” ■

### TAKE-HOME

► Updated guidelines on diabetic eye care from the International Council of Ophthalmology give evidence- and experience-based recommendations.

#### TIEN YIN WONG, MD, PHD

E: [tien\\_yin\\_wong@duke-nus.edu.sg](mailto:tien_yin_wong@duke-nus.edu.sg)

#### SRILAXMI BEARELLY, MD, MHS

P: 212/305-9535

Dr. Wong and Dr. Bearely have no related disclosures.

## OPTIC STEREO

(Continued from page 14)

new role for stereoscopic photography as a method to be used alongside OCT, to improve the capabilities of diagnosis and monitoring the course of glaucoma. ■

### References

1. Tham YC, et al. Global prevalence of glaucoma and projections of glaucoma burden through 2040: A systematic review and meta-analysis. *Ophthalmology*. 2014;121:2081-2090. doi:10.1016/j.ophtha.2014.05.013.
2. Resnikoff S, et al. Global data on visual impairment in the year 2002. *Bull World Health Organ*. 2004;82:844-851.
3. Bourne RRA, et al. Number of People Blind or Visually Impaired by Glaucoma Worldwide and in World Regions 1990 - 2010: A Meta-Analysis. *PLoS One*. 2016;11:e0162229.
4. Rossetti L, et al. Blindness and glaucoma: A multicenter data review from 7 academic eye clinics. *PLoS One*. 2015.
5. Rulli E, et al. Visual field loss and vision-related quality of life in the Italian Primary Open Angle Glaucoma Study. *Sci Rep*. 2018;8:619.
6. Quaranta L, et al. Quality of Life in Glaucoma: A Review of the Literature. *Adv Ther*. 2016;33:959-981.
7. Harwerth RS, et al. Ganglion cell losses underlying visual field defects from experimental glaucoma. *Invest Ophthalmol Vis Sci*. 1999;40:2242-2250.
8. Michelessi M, et al. Optic nerve head and fibre layer imaging for diagnosing glaucoma. *Cochrane database Syst Rev*. 2015;11:CD008803.
9. Stone RA, et al. Utility of digital stereo images for optic disc evaluation. *Invest Ophthalmol Vis Sci*. 2010;51:5667-5674.
10. Budenz DL, et al. Detection and prognostic significance of optic disc hemorrhages during the Ocular Hypertension Treatment Study. *Ophthalmology*. 2006;113:2137-2143.
11. Nema HV, Nema N. Diagnostic Procedures in Ophthalmology. [https://books.google.it/books?id=ksIDBAAQBAJ&dq=stereoscopic+vs+traditional+optic+nerve+photograph&hl=it&source=gbs\\_navlinks\\_s](https://books.google.it/books?id=ksIDBAAQBAJ&dq=stereoscopic+vs+traditional+optic+nerve+photograph&hl=it&source=gbs_navlinks_s). Accessed March 29, 2018.
12. Abbasi F, et al. Effectiveness of Amlexanox and Adcortyl for the treatment of recurrent aphthous ulcers. *J Clin Exp Dent*. 2016;18:368-372.
13. Fechtner RD, Lama P. Advances in optic nerve head analysis in glaucoma. *Semin Ophthalmol*. 1999;14:180-188.
14. Breusegem C, et al. Agreement and accuracy of non-expert ophthalmologists in assessing glaucomatous changes in serial stereo optic disc photographs. *Ophthalmology*. 2011;118:742-746.
15. Abrams LS, et al. Agreement among optometrists, ophthalmologists, and residents in evaluating the optic disc for glaucoma. *Ophthalmology*. 1994;101:1662-1667.
16. Michelessi M, et al. Optic nerve head and fibre layer imaging for diagnosing glaucoma. *Cochrane database Syst Rev*. 2015;11:CD008803.

#### FRANCESCO ODDONE, MD, PHD

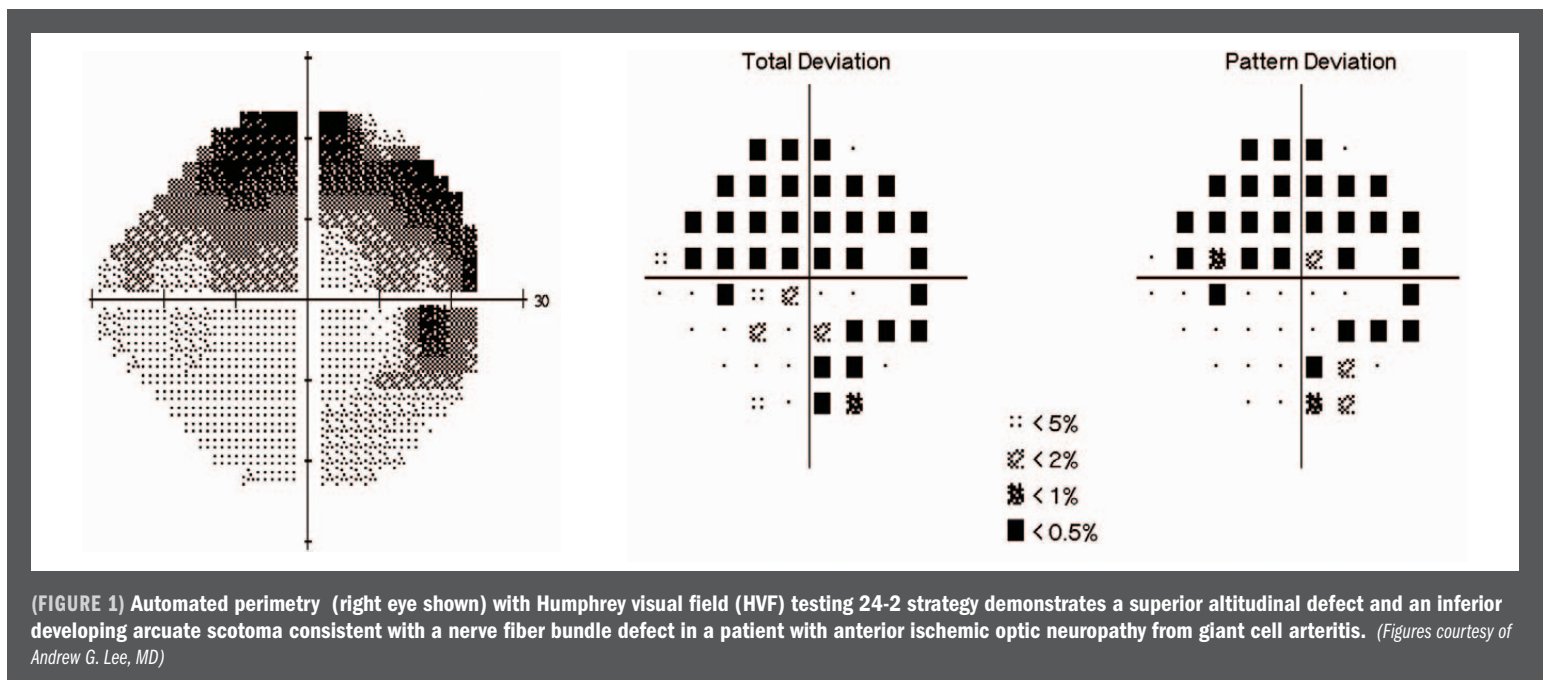
E: [oddonef@gmail.com](mailto:oddonef@gmail.com)

Dr. Oddone performs clinical, surgical and scientific activities at the IRCCS G.B. Bietti Foundation Britannic Hospital in Rome, Italy. Since 2015, he has been head of the Glaucoma Unit. Dr. Oddone is a consultant for Centervue, Allergan and Glaucom, and a speaker for Santen, Haag Streit, Glaucom and Omikron Italia.

# Exploring tocilizumab for giant cell arteritis cases

Drug shows promise; further studies may be needed for long-term safety profile, efficacy

**Neuro-Connection** By Iyza F. Baig, Alexis Pascoe, and Andrew G. Lee, MD



**G**iant cell arteritis (GCA) is a systemic vasculitis that produces a granulomatous inflammation of large- and medium-sized arteries, most commonly involving the aorta and extracranial branches of the carotid arteries.<sup>1,2,3,4</sup>

Classically affecting patients over the age of 50 years, GCA is known to be the most common primary vasculitis affecting Western countries.<sup>2,3,4</sup>

While headaches, myocardial infarction, stroke, and claudication of the jaw are important clinical manifestations of GCA, those relevant to an ophthalmological perspective include transient ischemic visual symptoms and permanent blindness (e.g., ischemic optic neuropathy or central retinal artery occlusion).<sup>1,3</sup>

Complications of the vasculitis can result from ischemia secondary to arterial occlusion, systemic inflammation, and aneurysm formation and rupture due to persistent ar-

terial wall injury<sup>1</sup>; therefore, prompt and effective control of inflammation is essential. High-dose corticosteroids (e.g., 1–1.5 mg/kg of oral prednisone per day or intravenous (IV) methylprednisolone) should be considered urgently in the treatment of GCA. Earlier treatment may lead to more rapid symptomatic relief of headache, normalization of inflammatory markers, and reduction or prevention of vision loss after initiation.<sup>1,5,6</sup>

While corticosteroids have significantly decreased the incidence of blindness in patients with GCA, studies have shown that vascular inflammation persists even after corticosteroid therapy, allowing for progressive occlusion of the affected vessels.<sup>1</sup>

In addition, since the majority of patients tend to flare as corticosteroid dosage is re-

duced, long-term treatment with a slow reduction of steroids is thereby necessary.<sup>3</sup>

Unfortunately, long-term corticosteroid use can lead to significant comorbidities such as infection, fractures, cataracts, diabetes, and even psychosis.<sup>3</sup>

Consultation with the primary-care provider and/or rheumatologist may be necessary to help with treatment and management of side effects.

For this reason, the search for corticosteroid-sparing treatment regimens in GCA has been under way. Prior randomized controlled tri-

als evaluating corticosteroid-sparing agents such as methotrexate and tumor necrosis factor inhibitors have failed or shown inconclusive or conflicting results.<sup>3,6</sup>

However, a randomized controlled trial

## TAKE-HOME

► **A randomized controlled trial has demonstrated a viable contender for maintaining corticosteroid remission in GCA: the interleukin-6 (IL-6) receptor inhibitor, tocilizumab (TCZ).**

Continues on page 20 : **Neuro**

## NEURO

( Continued from page 19 )

has finally demonstrated a viable contender for maintaining corticosteroid remission in patients with GCA: the interleukin-6 (IL-6) receptor inhibitor, tocilizumab (TCZ).<sup>5</sup>

The rationale for blocking the receptor for IL-6 is based on the cytokine's central role in regulating both innate and acquired immunities.<sup>3</sup> Produced by T-cells, B-cells, endothelial cells, fibroblasts, and macrophages, IL-6 has been shown to be increased in inflamed arteries, potentiating the inflammatory responses of GCA.<sup>3</sup>

Ophthalmologists should be aware of these newer agents including TCZ and should refer selected GCA patients for consideration of treatment in the appropriate clinical situation.

A study by Weyand et al (2000) suggested that disease activity in GCA correlates with serum levels of IL-6, and that compared to erythrocyte sedimentation rate (ESR), IL-6 may be a more sensitive biological marker for disease activity in GCA patients who were untreated and treated with corticosteroids.<sup>1</sup>

Consequently, numerous studies (including a phase II trial) examining TCZ were performed, and results suggested the high efficacy of the IL-6 receptor inhibitor in inducing and maintaining remission in GCA.<sup>2,4</sup>

More recently, the results of the much awaited GiACTA trial, a 1-year, multicenter, randomized, controlled, double blind trial, show significant promise in the use of TCS for inducing and maintaining remission in GCA.<sup>3,5</sup>

In the GiACTA trial, 251 patients were randomly assigned to one of four treatment groups:<sup>3</sup>

■ **162 mg of subcutaneous TCZ weekly + 26-week prednisone taper (cumulative prednisone dose = 1,862 mg)**

■ **162 mg of subcutaneous TCZ every two weeks + 26-week prednisone taper (cumulative prednisone dose = 1,862 mg)**

■ **Placebo + 26-week prednisone taper (cumulative prednisone dose = 3,296 mg)**

■ **Placebo + 52-week prednisone taper (cumulative prednisone dose = 3818 mg)**

Sustained remission was defined as normalization of C-reactive protein (<1 mg/dL) and absence of flare (signs and symptoms of GCA, ESR >30 mm/hour) from week 12 to week 52 while adhering to prednisone taper.<sup>5</sup>

Outcomes were measured at 52 weeks and included rates of corticosteroid-free remission maintained by each TCZ group compared with those of the placebo group treated with a 26-week prednisone taper and a 52-week taper prednisone taper.<sup>5</sup>

Results of the GiACTA trial showed that by 52 weeks, 56% of patients receiving TCZ weekly and 53% of those receiving it biweekly had achieved and sustained remission, compared to 14% of the placebo group on the 26-week

prednisone taper, and 18% of those on the 52-week prednisone taper.<sup>5</sup>

Furthermore, 23% and 26% of those on TCZ weekly and biweekly had a flare, respectively, compared to 68% of those on the 26-week prednisone taper, and 49% of those on the 52-week taper.<sup>5</sup>

Safety of TCZ was also evaluated: 15% and 14% of the weekly and biweekly TCZ groups respectively reported serious adverse events, while those in the placebo 26-week taper and 52-week taper reported 22% and 25% adverse events respectively.<sup>5</sup>

Infection was the most common adverse event in all groups, and occurred in 7% of those on weekly TCZ, 4% on biweekly TCZ, 4% of those on placebo and 26-week taper, and 12% of those on placebo and 52-week taper.<sup>5</sup>

In conclusion, GiACTA trial has demonstrated with a 1-year, randomized, placebo-controlled design that TCZ was more effective in sustaining corticosteroid-free remission than both placebo groups with 26-week and 52-week prednisone taper.<sup>5</sup>

Furthermore, weekly treatment with TCZ resulted in better control of disease activity than biweekly TCZ.<sup>5</sup> Some criti-

cisms have arisen since publication of the GiACTA trial,<sup>7,8</sup> and while further studies may be needed to characterize its long-term safety profile and efficacy, TCZ shows significant promise in the treatment of GCA.

Ophthalmologists should be aware of these newer agents including TCZ and should refer selected GCA patients for consideration of treatment in the appropriate clinical situation. ■

### References

1. Weyand CM, Fulbright JW, Hunder GG, Evans JM, Goronzy JJ. Treatment of giant cell arteritis: Interleukin-6 as a biologic marker of disease activity. *Arthritis and Rheumatism*. 2000;43:1041-1048.
2. Villiger PM, Prof, Adler S, MD, Kuchen S, MD, et al. Tocilizumab for induction and maintenance of remission in giant cell arteritis: a phase 2, randomised, double-blind, placebo-controlled trial. *Lancet*. 2016;387:1921-1927.
3. Unizony SH, Dasgupta B, Fishelova E, et al. Design of the tocilizumab in giant cell arteritis trial. *International Journal of Rheumatology*. 2013;2013:1-10.
4. Loricera J, Blanco R, Hernández JL, et al. Tocilizumab in giant cell arteritis: Multicenter open-label study of 22 patients. *Seminars in Arthritis and Rheumatism*. 2015;44:717-723.
5. Stone JH, Tuckwell K, Dimonaco S, et al. Trial of Tocilizumab in Giant-Cell Arteritis. *New England Journal of Medicine*. 2017;377:317-328.
6. Ferfar Y, Mirault T, Desbois AC, et al. Biotherapies in large vessel vasculitis. *Autoimmunity Reviews*. 2016;15:544-551.
7. González-Gay MA, Loricera J, Blanco R. Trial of Tocilizumab in Giant-Cell Arteritis. *New England Journal of Medicine*. 2017;377:1493.
8. Walker UA. Trial of Tocilizumab in Giant-Cell Arteritis. *New England Journal of Medicine*. 2017;377:1493-1495.



#### IYZA F. BAIG

E: [iyza.baig@uth.tmc.edu](mailto:iyza.baig@uth.tmc.edu)

Baig is affiliated with McGovern Medical School at The University of Texas Health Science Center in Houston (UTHealth), Houston.



#### ALEXIS PASCOE

E: [alexis.pascoe@uth.tmc.edu](mailto:alexis.pascoe@uth.tmc.edu)

Pascoe is affiliated with McGovern Medical School at The University of Texas Health Science Center in Houston (UTHealth), Houston.



#### ANDREW G. LEE, MD

E: [aglee@houstonmethodist.org](mailto:aglee@houstonmethodist.org)

Dr. Lee is affiliated with Department of Ophthalmology, Blanton Eye Institute, Houston Methodist Hospital, Houston; Baylor College of Medicine, Houston; adjunct professor of ophthalmology; Departments of Ophthalmology, Neurology, and Neurosurgery, Weill Cornell Medical College, Houston; clinical professor, UTMB Galveston, TX and the UT M.D. Anderson Cancer Center, Houston; and adjunct professor of ophthalmology, The University of Iowa Hospitals and Clinics, Iowa City, IA. The authors did not indicate any proprietary interests relevant to the subject matter.

## LIGHT-ACTIVATED

(Continued from page 1)

The capsid conjugates are delivered by intravitreal injection and selectively target the tumor cells in the choroid sparing the retina and other key ocular structures. This unique selectivity is due to the binding of the capsid conjugates to modified heparan sulfate proteoglycans (HSPGs) that are expressed on the tumor cell surface. The capsid protein is conjugated with a potent phthalocyanine photosensitizer, IRDye 700DX, that exerts its tumor cytotoxic effect through light-activation with a near-infrared 689-nm laser.

The mechanism of action has a dual selectivity. First, the capsid conjugates bind tumor cells selectively without binding other key eye structures and second, the laser beam activates the conjugated dye exclusively within the tumor generating potent cytotoxic oxygen free radical species that disrupt the tumor cell membrane, leading to targeted and acute tumor cellular necrosis, Dr. Scheffler said.

In preclinical ocular tumor rabbit models, animals were treated with two weekly doses of light activated AU-011 on day 1 and day 8. The results demonstrated complete necrosis in the tumors implanted in the choroid with no damage to the adjacent retina even in tumors measuring >10mm in thickness, Dr. Scheffler said.

The animal data showed a dose response effect, which means that with higher doses of the drug the tumor necrosis increased, while the retina and other healthy tissue were not affected, she said. The strength of this preclinical data enabled the Orphan Drug Designation by the FDA in 2015.

Dr. Scheffler presented the interim 6-month results on AU-011.

### STUDY DESIGN

The phase Ib/II trial is a 2-year, prospective, multicenter, open label design with single and multiple ascending dose cohorts, she said.

Three patients with choroidal melanoma received a single intravitreal administration of the capsid conjugate at each of three sub-therapeutic dose-escalating levels (20 µg, 40 µg, or 80 µg) followed by light-activation with a 689-nm laser at a fluence of 50 J/cm<sup>2</sup>. (Dr. Scheffler clarified that while this is a similar laser as used in photodynamic therapy, there was no verteporfin used).

The multiple ascending dose (MAD) phase of the study consisted of four additional cohorts of three patients each. In each cohort the number of intravitreal administrations was in-

creased up to three weekly treatments and the number of laser activations was increased to two applications on the same day, separated by 30 minutes. The objective of the MAD was to explore the maximum tolerated dose and regimen for the phase III clinical trials.

The primary trial objective was safety, with secondary outcomes including efficacy and immunogenicity.

### STUDY RESULTS TO DATE

There have been 22 patients treated to date, nine in the single ascending dose cohort, and 13 in the multiple ascending dose cohort.

"There were no treatment-related serious events or severe adverse events," Dr. Scheffler said.

Fundoscopic evaluation of patients after treatment showed that the posterior inflammation appears to start in the tumor and "is probably related to tumor necrosis."

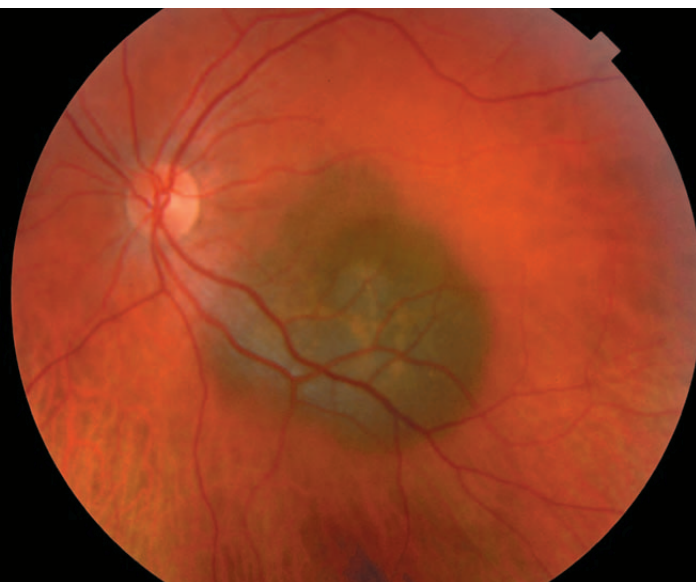
There was virtually no change in visual acuity (all patients followed for 6 months or longer were within one letter of baseline).

"This was regardless of where the tumor was located, including those that were right in the middle of the fovea or touching the optic nerve," she said.

In the three single-dose cohorts, several patients had stable disease at 12 months, even though this had been considered the sub-therapeutic dose, Dr. Scheffler said.

In the multiple dose cohorts, all patients maintained stable disease at follow-up and a

**A novel therapy (AU-011) on the horizon for small-to-medium choroidal melanomas aims to cure cancer while also saving vision—as shown in cases such as this one, in which the tumor is close to the critical retinal structures and radiation would cause significant vision loss.** (Image courtesy of Aura Biosciences Inc.)



There were no dose-limiting toxicities observed. Adverse events were manageable with standard of care treatments and had no further clinical sequelae. Pre-treatment visual acuity was maintained in all subjects that have been followed for 6 to 12 months, Dr. Scheffler said.

All adverse events were deemed mild to moderate, and included anterior or posterior inflammation (in 10 and 11 patients [n = 18], respectively), which started about 4 weeks after treatment. There was transient increased intraocular pressure in 6/18 patients.

Of note, the inflammation and the IOP increase were manageable to date with standard treatment and resolved without clinical sequelae.

"Interestingly, inflammation is an expected response to the mechanism of action of AU-011 as a result of the acute tumor cell necrosis, and may actually be beneficial in terms of creating a tumor-specific T-cell immune response," she said. "Rather than prevent this up front, we want to treat it once it happens."

number of patients had tumor shrinkage measured by ultrasound.

Dr. Scheffler said investigators are measuring tumor growth, and presuming that when there is no further growth the tumor is undergoing necrosis with no malignant potential any longer.

"Certainly, seeing tumor shrinkage and inflammation around the tumor at early time points is encouraging to confirm the biological activity of the drug, but the most important measure for efficacy is that the tumors have no further growth at longer follow up times with good vision preservation," Dr. Scheffler said. ■

#### AMY C. SCHEFLER, MD

P: 713/524-3434

This article was adapted from Dr. Scheffler's presentation at the 2018 meeting of the American Society of Retina Specialists. Dr. Scheffler is an investigator and consultant for Aura Biosciences.

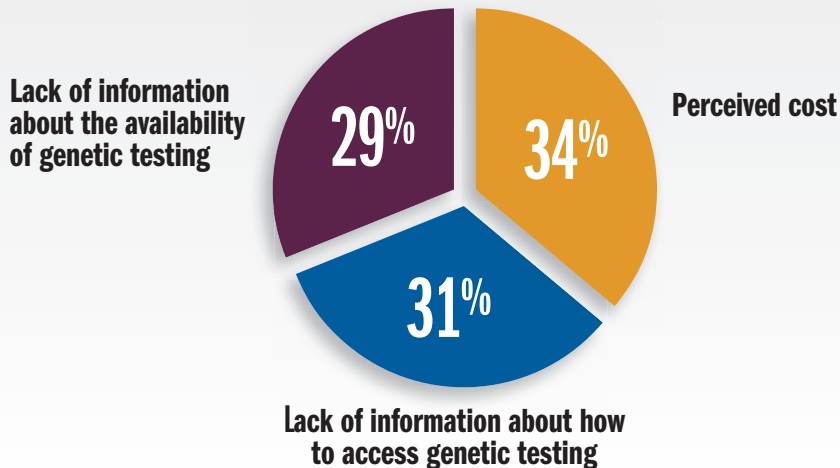
Special Report )

**DRUG & GENE THERAPY**

ADVANCES CONTINUE TO PROGRESS FOR PHARMACOLOGIC AND GENETIC TREATMENTS

**For the 40% of adults**

who had not received genetic testing, the most commonly cited reasons for not seeking genetic testing were the following:



## ACHROMATOPSIA: UNDERSTANDING THE RARE INHERITED RETINAL DISEASE

Ophthalmologists need to be aware initial symptoms typically appear in infancy, as this is a congenital disorder

By **Christine N. Kay, MD**; Special to Ophthalmology Times

### take-home

► A recent global survey shows achromatopsia remains relatively misunderstood and underdiagnosed, and individuals with this disease face a difficult journey in pursuit of an early and accurate diagnosis.

**I**n 1997, a book published by neurologist Oliver Sacks, MD, “The Island of the Colorblind,” revealed an unusual trait in the inhabitants of the small Micronesian island of Pingelap—they were born completely colorblind. Known on the island as maskun, which literally translates as “not see” in Pingelapese, the rare genetic disorder is better known as achromatopsia by the rest of the world.

Achromatopsia is an autosomal recessive disease that affects approximately 1:30,000 individuals and is associated with complete loss of cone function. It is most commonly caused by mutations in the *CNGB3* and *CNGA3* genes and is associated with severely reduced visual acuity and extreme photosensitivity, resulting in daytime blindness.

Due to a loss of cone cell function, patients have complete loss of color discrimination. Most patients with achromatopsia have an average visual acuity of 20/200, resulting in a diagnosis of legal blindness. Profound sensitivity to light during the day results in significant impairment in visual function, and many patients cope by wearing darkly tinted glasses to lessen the effect of light sensitivity.

Even though this inherited retinal disease was the focus of a popular book by the well-known Dr. Sacks, a recent global survey conducted by Achroma Corp. shows that this disease remains relatively misunderstood and underdiagnosed, and individuals with achromatopsia face a long and difficult journey in pursuit of an early and accurate diagnosis.

### DIVING DEEPER

In an effort to better understand and engage the achromatopsia community, the “Understanding the Achromatopsia Patient Experience” survey was conducted online in January 2018 on behalf of Achroma Corp. and in partnership with Applied Genetic Technologies Corp. (AGTC), a gene therapy company. The survey, distributed through Achroma Corp.’s network, was completed by 226 respondents who have been diagnosed with—or have a child who has been diagnosed with—achromatopsia.

Initial symptoms of achromatopsia typically appear in infancy, as this is a congenital disorder. Symptoms can include nystagmus (rapid involuntary eye movements), as well as photosensitivity and markedly reduced visual acuity.

According to the global survey, photosensitivity is reported as being the most debilitating and bothersome symptom of achromatopsia; on a 0–100 scale, adults with achromatopsia give photosensitivity a rating of 77 on severity and 75 on being bothersome.

This severe photoaversion significantly and negatively impacts their ability to function daily and takes an emotional toll on their health and wellness.

The majority of affected individuals reported that their photosensitivity had not changed over time (53% of adults and 82% of children).

Continues on page 28 : **Retinal disease**

## RETINAL DISEASE

(Continued from page 27)

However, more than one-third of adults believed that their photosensitivity had worsened over time. These individuals reported that they had taken additional steps to adapt and function. Primarily, 58% of individuals adapted by using eyewear with a darker tint or extreme gradient, 53% expanded their use of eyewear and 44% avoided the outdoors.

Regarding diagnosis, most patients in the survey described a long and circuitous route to correct diagnosis, with a relatively longer course to diagnosis for adults as compared to the children. Parents typically pursue answers from their general or pediatric healthcare providers, and see an average of four healthcare providers in a span of three years before receiving a diagnosis for their child, with 68% taking more than a year to receive a diagnosis after the initial onset of symptoms.

Twenty-three percent of children still received an incorrect diagnosis of retinal or cone dystrophy before being accurately diagnosed with achromatopsia. Adults with achromatopsia usually see an average of seven healthcare providers over a span of more than five years to receive the correct diagnosis. More than one-third of these individuals were misdiagnosed with retinal or cone dystrophy before receiving the correct diagnosis of achromatopsia.

**Parents typically pursue answers from their general or pediatric healthcare providers, and see an average of four healthcare providers in a span of three years before receiving a diagnosis for their child, with 68% taking more than a year to receive a diagnosis after the initial onset of symptoms. Twenty-three percent of children still received an incorrect diagnosis of retinal or cone dystrophy before being accurately diagnosed with achromatopsia.**

The survey results indicate that only 58% of adults and 65% of children with achromatopsia have received genetic testing to confirm the correct diagnosis and the underlying gene responsible.

In the past, the lack of genetic confirmation of disease could be blamed on the lack of therapeutic options. Due to this, many ophthalmologists and their achromatopsia patients

**Adults with achromatopsia usually see an average of seven healthcare providers over a span of more than five years to receive the correct diagnosis. More than one-third of these individuals were misdiagnosed with retinal or cone dystrophy before receiving the correct diagnosis of achromatopsia.**

**The survey results indicate that only 58% of adults and 65% of children with achromatopsia have received genetic testing to confirm the correct diagnosis and the underlying gene responsible.**

resigned themselves to simply managing the disease and never sought out genetic testing to secure or confirm a correct diagnosis. For the 40% of adults who had not received genetic testing, the most commonly cited reasons for not seeking genetic testing were the following:

- Perceived cost (34%)
- Lack of information about how to access genetic testing (31%)
- Lack of information about the availability of genetic testing (29%)

For parents of children with achromatopsia who had not received genetic testing, the most commonly cited reason was lack of information about accessing genetic testing (27%).

However, even in the past few years, the landscape for achromatopsia has radically changed.

With several gene therapy studies in achromatopsia under way, it becomes imperative that ophthalmologists have a conversation with their inherited retinal disease patients about receiving genetic testing.

Currently, members of the Foundation Fighting Blindness (FFB) registry who reside in the United States and have a clinical diagnosis of an orphan inherited retinal dystrophy studied by the foundation can participate in a free genetic testing and ocular genetic counseling study with the assistance of their eye care professional. This research study, which is IRB-approved and available for a finite time, is available through the FFB registry ([www.myretinatracker.org](http://www.myretinatracker.org)).

By knowing their specific gene mutation, achromatopsia patients, as well as others living with inherited retinal diseases, may have

the opportunity to participate in applicable clinical trials. These clinical trials are investigating potential treatments for the condition while also advancing the scientific understanding of achromatopsia.

AGTC is currently recruiting for two phase I/II clinical trials for individuals with achromatopsia caused by mutations in either the CNGB3 or the CNGA3 gene.

Information about the phase I/II clinical trial in achromatopsia caused by CNGA3 can be found at [ClinicalTrials.gov](http://ClinicalTrials.gov) under the trial identifier number NCT02935517, while the phase I/II clinical trial in achromatopsia caused by CNGB3 can be found under the trial identifier number NCT02599922. ■

*Author's Note: Regarding these survey results, it is important to note that the survey was completed by those who were fortunate enough to receive a correct diagnosis and therefore become involved in Achroma Corp.'s network ([www.achromacorp.org](http://www.achromacorp.org)). Due to selection bias, the rates of misdiagnosis and barriers to genetic testing are likely much higher than captured by this survey.*

### References

1. Sharpe LT, Stockman A, Jagle H, Nathans J. Opsin genes, cone photopigments, color vision, and color blindness. In: Gegenfurtner K, Sharpe LT, eds. *Color Vision: from Genes to Perception*. Cambridge, UK: Cambridge University Press; 1999:3-52.
2. Achroma Corp. announces global survey results of 226 people with achromatopsia. Achroma Corp. <https://www.achromacorp.org/PatientJourney.html>. Accessed June 27, 2018.

**CHRISTINE N. KAY, MD**

P: 352/371-2800

Dr. Kay is a principal investigator in the AGTC-sponsored gene therapy trials for CNGA3 and CNGB3 achromatopsia.

# Non-coding mutations identified as corneal endothelial dystrophy cause

Etiology can provide more accurate predictions of disease progression, associated risks

By **Cheryl Guttman Krader**; Reviewed by **Alison Hardcastle, PhD, and Petra Liskova, MD, PhD**

**RESEARCHERS STUDYING** families affected by posterior polymorphous corneal dystrophy 4 (PPCD4) have identified new mutations causing the rare autosomal-dominant corneal endothelial dystrophy.



Dr. Hardcastle

The discovery and related investigations that are described in a recent publication [Liskova P, et al. *Am J Hum Genet.* 2018;102:447–459.] provide insight into the molecular basis of PPCD and have implications for both clinical care and genetic researchers, said Alison Hardcastle, PhD, and Petra Liskova, MD, PhD.



Dr. Liskova

Studying individuals from a Czech family and using linkage analysis, the investigators identified a single locus mapping to chromosome 8q22.3–q24.12. Through whole-genome sequencing, a unique variant (c.20+544G>T) was found in the locus that was within intron 1 of GRHL2.

Targeted screening of GRHL2 regulatory regions in individuals from unrelated, previously unsolved PPCD4-affected families led to the discovery of two additional unique genetic variants in the intronic regulatory region of GRHL2. In vitro tests showed that the three PPCD4 variants induced increased expression of GRHL2.

Histological evaluation and immunostaining studies of corneal tissue from a PPCD4-affected eye and unaffected controls showed that endothelial cells in the diseased eyes inappropriately expressed GRHL2 as well as epithelial markers (E-cadherin and cytokeratin 7), indicating that the cells had transitioned from an endothelial to an epithelial-like cell type.

Dr. Hardcastle and Dr. Liskova explained that the mutations discovered in patients with PPCD4 and those found previously in PPCD1- and PPCD3-affected families all involve genes that are key regulators of pathways involved

in epithelial to mesenchymal transition/mesenchymal to epithelial transition (EMT/MET) pathways.

“An imbalance in transcription factors involved in the EMT/MET pathways appears to be a convergent disease mechanism leading to dysfunction of the endothelial barrier and the development of PPCD,” said Dr. Hardcastle, professor of molecular genetics, UCL Institute of Ophthalmology, University College London, London. “The mutations cause either an increase or decrease in expression of the transcription factors that causes the cells to transition to an epithelial-like cell state.”

## CLINICAL RELEVANCE

Dr. Hardcastle and Dr. Liskova noted that elucidation of the genetic causes for PPCD has several clinical ramifications.

“Traditionally, disorders leading to corneal opacity have been treated surgically, and knowledge of the underlying molecular causes has not been considered essential for patient management,” said Dr. Liskova, associate professor, Departments of Ophthalmology and Pediatrics and Adolescent Medicine, First Faculty of Medicine, Charles University, Prague, Czech Republic. “However, understanding the genetic cause is becoming increasingly important and relevant in all medical fields, including ophthalmology.”

Dr. Liskova noted that in some patients, PPCD is phenotypically indistinguishable from congenital hereditary endothelial dystrophy.

“The ability to identify disease-causing mutations would facilitate an accurate diagnosis. Because congenital hereditary endothelial dystrophy may be associated with hearing loss, it is recommended

that affected children undergo regular evaluations of auditory function. This type of follow-up is not needed for children with PPCD,” said Dr. Liskova.

There are also implications for counseling of patients with PPCD.

Dr. Liskova explained, “Patients with both

Mendelian disorders and complex disorders seek genetic counseling and testing. By dissecting the genetic cause of PPCD we can provide more accurate predictions of disease progression, associated risks, such as secondary glaucoma development, and if a corneal transplant may be necessary as disease progresses,” she said.

Dr. Liskova added, “Knowledge of the underlying genetic cause is fundamental to understanding disease mechanisms and facilitates genetic testing to determine if individuals are at risk of developing disease. Ophthalmologists have an essential role in informing patients and their families about genetic testing.”

Obtaining a clearer understanding of pathogenic mechanisms for disease development also opens up opportunities for identifying targeted therapies, and as an accessible tissue, the cornea is well suited for genetic treatment.

“Switching off inappropriately expressed genes could be considered as a possible therapeutic option for corneal dystrophies,” said Dr. Liskova.

“We have recently demonstrated the potential utility of a gene targeted therapy for Fuchs corneal endothelial dystrophy. We found that treating patient cells with a targeted antisense oligonucleotide reversed toxic effects caused by a mutation in TCF4. In the future, a similar type of gene-directed therapy could be applicable for PPCD,” said Dr. Hardcastle.

The discovery of the genetic cause of PPCD4 was possible because of the use of whole-genome sequencing (WGS).

“Whole-genome sequencing enabled interrogation of the entire genome rather than just the protein coding portion that is more typically and routinely investigated,” said Dr. Liskova. ■

## Take Home

► Understanding the genetic cause for PPCD is becoming increasingly important and relevant in all medical fields, including ophthalmology.

**PETRA LISKOVA, MD, PHD**

E: [petra.liskova@ff1.cuni.cz](mailto:petra.liskova@ff1.cuni.cz)

**ALISON HARDCASTLE, PHD**

E: [a.hardcastle@ucl.ac.uk](mailto:a.hardcastle@ucl.ac.uk)

Dr. Liskova and Dr. Hardcastle have no relevant disclosures.



# Small drop delivers big advancement

Novel smart device microdoses the eye to precisely target total exposure to drops

By Sean Ianchulev, MD, MPH; Special to Ophthalmology Times

**FROM MY PERSPECTIVE**, first as an ophthalmologist and as someone who has brought many innovative technologies into our field, I have come to realize how antiquated and inadequate is the existing paradigm of topical drug delivery.

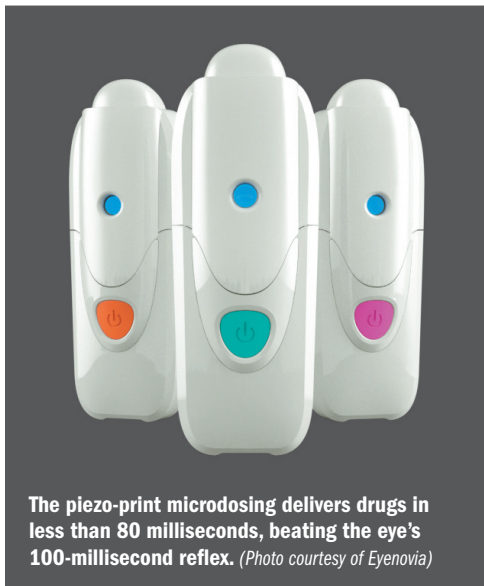There is virtually no other situation in medicine where physicians prescribe a therapeutic to patients knowing that, most of the time, they do not receive the correct dose. In the case of pills and injectable drugs, we know that if have prescribed 250 mg of Augmentin or 10 units of insulin, for example, and that is what the patient gets.

When clinicians prescribe one drop of timolol twice a day, however, studies have demonstrated that patients get a drop into their eye only about half the time. When they do manage to get drops in the eye, patients often administer between 2 and 7 drops, or a 100% to 600% overdose.<sup>1-7</sup> Much of this excess goes directly into the blood stream through nasolacrimal drainage, explaining not only the high incidence of ocular side effects, but in the case of cardiotropic drop therapies like beta-blockers, systemic ones as well (eg, slowing heart and respiratory rates).

Another concern patients have about their drops is the frequency with which they run out of their medication because of the overdosing. This concern has been voiced by consumer advocacy groups who say patients are paying too much for wasted medication. They make the case that companies have a responsibility to provide drugs in accurate dosing containers which can deliver smaller drops, precisely as prescribed. This was escalated recently all the way to the Supreme Court which refused to consider industry's appeal.<sup>8</sup>

## OVERDOSING THE EYE

Even when a single drop is administered correctly, about half the time, the eye is overdosed by 300%. The eye contains about 6 to 7 $\mu$ L of tear film and yet the legacy eye dropper—the mainstay of topical eye delivery for more than 100 years—dispenses about 30  $\mu$ L to 50 microliters depending the dropper. Hence, the



The piezo-print microdosing delivers drugs in less than 80 milliseconds, beating the eye's 100-millisecond reflex. (Photo courtesy of Eyenovia)

patient receives more drug, and more preservative, leading to more adverse events. About half of glaucoma patients experience adverse events from their drops,<sup>9</sup> and only half are adherent to their therapy.<sup>1-7</sup>

## Take-home

► Piezo-print technology directs a precise stream of micro-droplets to the ocular surface—in less than a blink of an eye.

Not only are the issues associated with drops a barrier to patients' compliance, they are a stumbling block new drugs must overcome in clinical trials. For example, recent trials have shown adverse events associated with otherwise promising news agents, which can obscure the medication's potential.

## PRECISELY TARGETED

Novel high-precision microtherapeutic delivery technology is being developed to change the way drops are administered to the ocular surface. Previous attempts with sprays have been tried and failed, because aerosols are imprecise and liquid jet sprays are hard on the eye. Instead, this technology uses breakthrough piezo-print technology which creates a micronized droplet stream. Piezo-print technology is how inkjet printers revolutionized the print industry, by using its ability to delivery pixel-sharp fluid stream of droplets to create elaborate images. High-precision piezo-print microdosing technology is leading the way with what we believe can replace the century-year-old legacy eyedropper and dramatically improve the

precision of topical drug delivery. New technology is poised to help usher in next-generation micro-therapeutics that will result in more than an 80% reduction in the eye's in exposure to the preservative and drug. Piezo-print microdosing delivers drugs in less than 80 milliseconds, beating the eye's 100-millisecond blink reflex. The technology also integrates smart electronics, allowing for dose monitoring thus enhancing compliance and disease management in a whole new area of smart microtherapeutics.

## GLAUCOMA, MYOPIA, IN-OFFICE DILATION

When considering the best place to go with this technology, glaucoma was the obvious choice: it is a blinding disease, compliance is a major problem, and patients take the drugs for life. It is further realized that there is no FDA approved therapy for chronic angle-closure glaucoma, which accounts for 10% and 50% of all glaucoma diagnoses in the United States and China, respectively.<sup>10</sup> This indication is being pursued for an underserved population, and then following with expanded indications in the larger glaucoma market.

There is also interest in progressive myopia, it is recognized as a growing epidemic: about one-third of all American and European adults are myopic.<sup>11,12</sup> Multiple randomized controlled Studies from academic collaborative groups have shown that atropine slows the development of myopia by 60% to 70%, and its use is supported by a position paper from the American Academy of Ophthalmology citing level 1 evidence.<sup>13</sup> Yet, there is no FDA approved drug because atropine needs to be administered in very low doses to allow for tolerability due to its side effects. This is a perfect candidate for microdosing technology, and we are preparing to initiate a phase III program for FDA registration during the next 12 months. Microdosing and the use of smart technology is a great fit for this savvy patient population who are not receptive to legacy eye drop delivery.

Also being explored is MicroStat for pharmacologic mydriasis; it would be a potential first-in-class fixed-combination microformulation of phenylephrine 2.5% and tropicamide 1%.

More than 80 million people a year receive

dilated office exams<sup>14</sup> and they overwhelmingly complain, finding it very unfriendly, awkward, and uncomfortable. Current preparations essentially “overdose” the eye; MicroStat can deliver the same efficacy as the drop that overdoses by 300%.

### IMPROVING COMPLIANCE, OUTCOMES

Using smart technology to precisely deliver drug to the corneal surface and thereby minimizing adverse events will define a whole new generation of smart microtherapeutics. Microdosing can be applied to many existing ocular drugs that are associated with significant toxicity side effects (e.g., hyperemia, prostaglandin-associated periorbitopathy).

When drugs are delivered precisely, clinicians can improve compliance, which means more treatment effect and better patient outcomes will follow.

Smart technology can make this happen. Drug makers will benefit from better compliance with more prescribers and revenue. Everyone will be happier, including insurers. Drugs are approved for efficacy, but patients and insurers buy effectiveness, after discounting for poor compliance.

There is a huge gap between what is shown in a clinical trial and what happens in the real world. When people run out of their drops, that is not a part of the study.

The aim is to price microdose agents in line

with what patients and insurers pay for today’s branded medications—and to have technology adopted as widely as possible and improve as many lives as possible. ■

### References

- Okeke CO, Quigley HA, Jampel HD, et al. Adherence with topical glaucoma medication monitored electronically: the Travatan Dosing Aid Study. *Ophthalmology*. 2009;116(2):191-199.
- Stone JL, Robin AL, Novack GD, et al. An objective evaluation of eye-drop instillation in glaucoma patients. *Arch Ophthalmol*. 2009;127(6):732-736.
- Hennessy A, Robin AL, Katz J, Covert D. Videotaped evaluation of eye drop instillation in glaucoma patients with visual impairment or moderate to severe visual field loss. *Ophthalmology*. In press.
- Tudor CG. Early Refill Edits on Topical Ophthalmic Products. Baltimore, MD: Centers for Medicare & Medicaid Services, US Department of Health & Human Services; 2010.
- Geyer O, Bottone EJ, Podos SM, et al. Microbial contamination of medications used to treat glaucoma. *Br J Ophthalmol*. 1995;79(4):376-379.
- Leske MC, Heijl A, Hyman L, et al; EMGT Group. Predictors of long-term progression in the Early Manifest Glaucoma Trial. *Ophthalmology*. 2007;114(11):1965-1972.
- Tsai T, Robin AL, Smith JP 3rd. An evaluation of how glaucoma patients use topical medications: a pilot study. *Trans Am Ophthalmol Soc*. 2007;105:29-33; discussion 33-35.
- Gresko J. Drug companies want Supreme Court to take eye drop dispute. *Associated Press*. March 31, 2018. <https://www.apnews.com/8c76eae40b740718e32d124301bd701>. Accessed June 25, 2018.
- Parrish RK, Palmberg P, Sheu WP; XLT Study Group. A comparison of latanoprost, bimatoprost, and travoprost in patients with elevated intraocular pressure: a 12-week, randomized, masked-evaluator multicenter study. *Am J Ophthalmol*. 2003;135(5):688-703.
- Aung T, Ang LP, Chan SP, Chew PT. Acute primary angle-closure: long-term intraocular pressure outcome in Asian eyes. *Am J Ophthalmol*. 2001;131(1):7-12.
- Vitale S, Ellwein L, Cotch MF, et al. Prevalence of refractive error in the United States, 1999-2004. *Arch Ophthalmol*. 2008;126:1111-1119.
- Williams KM, Verhoeven VJ, Cumberland P, et al. Prevalence of refractive error in Europe: the European Eye Epidemiology (E[3]) Consortium. *Eur J Epidemiol*. 2015;30:305-315.
- Pineles SL, Kraker RT, VanderVeen DK, et al. Atropine for the prevention of myopia progression in children. *Ophthalmology*. 2017;124(12):1857-1866. [https://www.aaojournal.org/article/S0161-6420\(17\)31675-5/fulltext](https://www.aaojournal.org/article/S0161-6420(17)31675-5/fulltext)
- American Optometric Association. State of the Optometric Profession. 2013. Available from: [https://www.aoa.org/Documents/news/state\\_of\\_optometry.pdf](https://www.aoa.org/Documents/news/state_of_optometry.pdf). Accessed July 3, 2018.



**SEAN IANCHULEV, MD, MPH**

E: [tianchul@yahoo.com](mailto:tianchul@yahoo.com).

*Dr. Ianchulev is professor of ophthalmology and director of innovation and technology at New York Eye and Ear Infirmary of Mount Sinai.*

*Dr. Ianchulev reports he is founder of Eyenovia and Iantech Technologies; chairman of the board for Iantech Technologies and on the board of Eyenovia; and the CEO of Eyenovia.*

## Eyenovia’s EYN PG21 study prepares for phase III trials

**EYENOVIA INC.** announced positive results of its EYN PG21 proof-of-concept study of microdose latanoprost for the lowering of intraocular pressure (IOP) and patient usability, according to a prepared statement.

The EYN PG21 clinical study investigated the medication administration effectiveness and IOP lowering effect of microdose latanoprost 0.005% in 60 eyes of 30 healthy volunteers.

Participants received once daily microdose treatment over 2 consecutive days and underwent diurnal (4 times/day) IOP assessments. The primary outcome was success of microdose delivery, with additional outcomes evaluating diurnal IOP change each day.

In the study, after a brief medication administration training session, investigators successfully administered high-precision piezo-print latanoprost with a single spray 95% of the time.

A separate evaluation of patient self-administration showed an 88% success rate following limited training. This is a substantive improvement from the 39%-47% success rate reported in the literature using a conventional eyedropper.

In addition, each single medication administration was within 1 µL of the prescribed dose and the tear capacity of the eye. This differs from traditional eyedropper administration, which may deliver as much as 300% more drug than the eye can hold with high variability of dosing.

The study results also demonstrated that, while reducing drug administration volume by 75% by delivering the microdose accurately and directly on the corneal surface, piezo-print micro-formulated latanoprost achieved a very robust reduction in diurnal IOP of up to 29%

from baseline unmedicated IOP, according to the statement.

This is consistent with the reported reduction of up to 26% achieved with the same concentration of standard latanoprost eye drops.

Sean Ianchulev, MD, MPH, Eyenovia’s Chief Executive Officer and Chief Medical Officer, commented, “We believe these compelling results further validate Eyenovia’s high-precision microdosing smart technology and build on the positive results from our phase II mydriasis study.

“These data are very informative for all of our upcoming phase III programs in prevention of myopia progression, chronic angle closure glaucoma and mydriasis by demonstrating that medications applied with our piezo-print technology are both effective and easy for patients to use,” Dr. Sean Ianchulev said. ■

# Refractive Cataract Surgery:

## Elevating the premium experience with FLACS

Blake K. Williamson, MD, MPH, MS



*Dr. Williamson is in private practice at Williamson Eye Center, Baton Rouge, LA, where he specializes in refractive cataract surgery and minimally invasive glaucoma surgery. He is a paid consultant to Johnson & Johnson Surgical Vision, Inc.*

When I began my career as a practicing ophthalmologist a few years ago, I wanted to build the refractive cataract surgery segment in our practice. I added femtosecond laser-assisted cataract surgery (FLACS) to our program because I believed in its precision and reproducibility and was committed to having this technology available to serve my patients.

In the year following its launch, we performed over 1000 FLACS cases. Our experience proved it was a win-win-win situation for patients, surgeons, and our practice. Contrary to some persisting beliefs, we found that with proper planning, FLACS could be easily integrated without decreasing surgical efficiency. FLACS also added value to our practice by building its reputation and premium channel.

### Clinical observations

Controversy continues to surround FLACS, with surgeons who have not yet adopted it citing insufficient evidence regarding its benefits compared with conventional cataract surgery. Many of the earlier comparative studies, however, were conducted with older-generation lasers/software and involved surgeons new to the technology. Findings from meta-analyses provide a

counterposition by showing evidence that FLACS can have advantages.<sup>1-3</sup>

Speaking from my personal experience, I consistently see clear corneas on postop day 1 following FLACS and the rapid return of crisp vision. It is also my impression that patients who had FLACS are not just “20/happy” on the first day after surgery, but are what I describe as “20/heck yeah”. The FLACS patients are more than just satisfied with their vision, they are ecstatic. Furthermore, they seem eager to share their positive experience with family and friends, as well as on social media, making them a valuable source of word-of-mouth referrals.

### Benefits for surgeons

The idea that FLACS reduces surgical efficiency is another lingering concern that can make surgeons reluctant to adopt the procedure. With careful planning, however, this can be avoided, and surgeons can even use FLACS to make themselves more efficient. Because I was busy performing 25 to 35 phacoemulsification procedures in a half-day surgical schedule, we implemented a 2-surgeon “shooter” system that facilitates patient flow and allowed us to avoid any slowdown. In this approach, the “shooter” working in the laser suite performs the laser portion of the procedure for my monofocal lens patients, while I move between our 2 operating rooms (ORs) completing the manual steps of the procedure. I still do the femtosecond laser treatment for all toric and presbyopia-correcting intraocular lens (IOL) cases, but because capsulotomy, lens segmentation/fragmentation, and arcuate incisions are already done before the patient is brought to the OR, it takes less time and

is easier to complete each FLACS case than if I were doing a manual case. Consequently, I have been able to add 2 more cases to each hour of the surgical schedule.

### Getting started

Perhaps among the main barriers to adoption of a femtosecond laser for cataract surgery is concern about the required financial investment. This obstacle, however, is removed through currently available femtosecond laser rental programs that are enabling access to the technology without a large capital requirement upfront and with the option to return the laser within a certain time period, no questions asked.

We began our FLACS program using a rented system, but we soon found that buying the equipment was a better option. There is no question that purchasing a femtosecond laser is a large expense, but FLACS brings a premium patient experience and empowers me to seamlessly elevate my practice.

After researching several platforms, I chose the CATALYS® Precision Laser System (J&J Vision). The CATALYS® system has an intuitive user interface that is easy to navigate and helps to minimize the learning curve. It reliably creates tag- and tear-free capsulotomies that are almost always free floating. In addition, it allows centration of the capsulotomy on the scanned capsular bag and the visual axis (as opposed to the pupillary axis).

Another attribute of the CATALYS® system is its integrated optical coherence tomography (OCT) technology. The OCT imaging offers highly precise and personalized treatments, including intrastromal and anterior penetrating arcuate incisions.

### Counseling conversations

After patients complete their initial cataract evaluation in our clinic, a technician gives them a tablet and asks them to watch a short video that describes how cataract surgery has evolved and can now be done with a laser. It shows the differences between manual phacoemulsification and FLACS and concludes with an overview of our surgical options menu.

Because we believe that there is no one-size-fits-all solution for cataract patients, we offer 3 options. The first option is traditional phacoemulsification with a monofocal IOL and the expectation of needing to wear bifocal glasses. The second option is for patients with astigmatism and includes FLACS with arcuate incisions and





implantation of a monofocal or toric lens as needed, allowing for crisp distance vision without the need for bifocal glasses. The third option is FLACS with a presbyopia-correcting IOL to reduce the need to wear glasses across a broader range of distances.

I see patients after they have watched the video. I talk to them about their goals and the risks and benefits of cataract surgery and FLACS. I assure each patient that they will have a good, safe surgery regardless of which option they choose. I find that patients equate the word "laser" with precision, and they don't want a procedure that is less precise even if it still delivers good outcomes. To let them know that my confidence in the procedure is real, I tell patients that I recently performed my mother's cataract surgery and recommended FLACS for her.

I explain that FLACS won't be fully covered by insurance. We believe, however, that financial ability should not prohibit any patient from choosing FLACS. Therefore, we have financing plans that make these advanced procedures available to everyone. I give patients an idea of cost before they see my surgical counselor because patients want to know. This also helps prevent sticker shock when they visit with the counselor who goes into detail on the financials after reviewing the patient's insurance.

I make sure patients understand that cataract surgery is a one-time procedure that will affect their vision for the rest of their life. We know that people highly value great vision

regardless of their socioeconomic status, and 60% of my cataract surgery population last year opted for FLACS.

### Final thoughts

In my opinion, FLACS may result in more satisfied patients and may add economic value. In addition, currently available trialing opportunities and creative workflow strategies should lessen concerns that might make cataract surgeons reluctant to adopt FLACS. Therefore, the decision to add FLACS should be a no-brainer for any practice offering refractive cataract surgery.

### REFERENCES

1. Popovic M, Campos-Möller X, Schlenker MB, Ahmed IIK. Efficacy and safety of femtosecond laser-assisted cataract surgery compared with manual cataract surgery: a meta-analysis of 14567 eyes. *Ophthalmology*. 2016;123(10):2113–2126.
2. Chen X, Xiao W, Ye S, et al. Efficacy and safety of femtosecond laser-assisted cataract surgery versus conventional phacoemulsification for cataract: a meta-analysis of randomized controlled trials. *Sci Rep*. 2015;5:13123.
3. Ye Z, Li Z, He S. A meta-analysis comparing postoperative complications and outcomes of femtosecond laser-assisted cataract surgery versus conventional phacoemulsification for cataract. *J Ophthalmol*. 2017;2017:3849152.

## INDICATIONS AND IMPORTANT SAFETY INFORMATION for the CATALYS Precision Laser System

**INDICATIONS** The CATALYS Precision Laser System is indicated for use in patients undergoing cataract surgery for removal of the crystalline lens. Intended uses in cataract surgery include anterior capsulotomy, phacofragmentation, and the creation of single plane and multi-plane arc cuts/incisions in the cornea, each of which may be performed either individually or consecutively during the same procedure.

**CONTRAINDICATIONS** The CATALYS System is contraindicated in patients with corneal ring and/or inlay implants, severe corneal opacities, corneal abnormalities, significant corneal edema or diminished aqueous clarity that obscures OCT imaging of the anterior lens capsule, patients younger than 22 years of age, descemetocoele with impending corneal rupture, and any contraindications to cataract surgery.

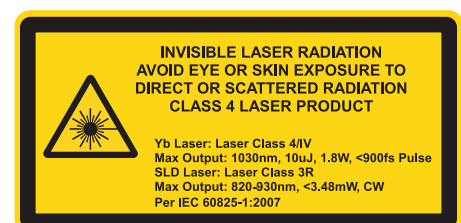
**WARNINGS** Prior to INTEGRAL GUIDANCE System imaging and laser treatment, the suction ring must be completely filled with sterile buffered saline solution. If any air bubbles and/or a meniscus appear on the video image before treatment, do not initiate laser treatment. Before initiating laser treatment, inspect images created from the OCT data, surface fits, and overlaid pattern in both axial and sagittal views, and review the treatment parameters on the Final Review Screen for accuracy. Safety margins for all incisions are preserved only if Custom Fit Adjustments to ocular surface(s) are applied in accordance with the instructions for use. Purposeful misuse of the Custom Fit Adjustment to ocular surfaces can result in patient injury and complication(s), and therefore must be avoided. Standard continuous curvilinear capsulorhexis (CCC) surgical technique must be used for surgical removal of the capsulotomy disc. The use of improper capsulotomy disc removal technique may potentially cause or contribute to anterior capsule tear and/or a noncircular, irregularly shaped capsulotomy. Verify that the suction ring is correctly connected to the disposable lens component of the LIQUID OPTICS Interface during the initial patient docking procedure.

**PRECAUTIONS** The CATALYS System has not been adequately evaluated in patients with a cataract greater than Grade 4 (via LOCS III); therefore no conclusions regarding either the safety or effectiveness are presently available. Cataract surgery may be more difficult in patients with an axial length less than 22 mm or greater than 26 mm, and/or an anterior chamber depth less than 2.5 mm due to anatomical restrictions. Use caution when treating patients who may be taking medications such as alpha blockers (e.g. Flo-max) as these medications may be related to Intraoperative Floppy Iris Syndrome (IFIS); this condition may include poor preoperative dilation, iris billowing and prolapse, and progress intraoperative miosis. These conditions may require modification of surgical technique such as the utilization of iris hooks, iris dilator rings, or viscoelastic substances. Surgical removal of the cataract more than 30 minutes after the laser capsulotomy and laser lens fragmentation are unknown. The LIQUID OPTICS Interface is intended for single patient use only. Full-thickness corneal cuts or incisions should be performed with instruments and supplies on standby, to seal the eye in case of anterior chamber collapse or fluid leakage. Patients who will undergo full-thickness corneal incisions with the CATALYS System should be given the same standard surgical preparation as used for patients undergoing cataract surgery for the removal of the crystalline lens. During intraocular surgery on patients who have undergone full-thickness corneal incisions with the CATALYS System, care should be taken if an eyelid speculum is used, in order to limit pressure from the speculum onto the open eye. Patients who will be transported between the creation of a full-thickness corneal incision and the completion of intraocular surgery should have their eye covered with a sterile rigid eye shield, in order to avoid inadvertent eye injury during transport. Patients must be able to lie flat and motionless in a supine position and able to tolerate local or topical anesthesia.

**ADVERSE EFFECTS** Complications associated with the CATALYS System include mild Petechiae and subconjunctival hemorrhage due to vacuum pressure of the LIQUID OPTICS Interface Suction ring. Potential complications and adverse events generally associated with the performance of capsulotomy and lens fragmentation, or creation of a partial-thickness or full-thickness cut or incision of the cornea, include: Acute corneal clouding, age-related macular degeneration, amaurosis, anterior and/or posterior capsule tear/rupture, astigmatism, capsulorhexis notch during phacoemulsification, capsulotomy/lens fragmentation or cut/incision decentration, cells in anterior chamber, choroidal effusion or hemorrhage, conjunctival hyperemia/injection/erythema/chemosis, conjunctivitis (allergic/viral), corneal abrasion/depithelization/epithelial defect, corneal edema, cystoid macula edema, Descemet's detachment, decentered or dislocated intraocular lens implant, diplopia, dropped or retained lens, dry eye/superficial punctate keratitis, edema, elevated intraocular pressure, endothelial decompensation, floaters, glaucoma, halo, inflammation, incomplete capsulotomy, intraoperative floppy iris syndrome, iris atrophy/extrusion, light flashes, meibomitis, ocular discomfort (e.g., pain, irritation, scratchiness, itching, foreign body sensation), ocular trauma, petechiae, photophobia, pigment changes/pigment in corneal endothelium/foveal region, pingueculitis, posterior capsule opacification, posterior capsule rupture, posterior vitreous detachment, posteriorly dislocated lens material, pupillary contraction, red blood cells in the anterior chamber (not hypHEMA), residual cortex, retained lens fragments, retinal detachment or hemorrhage, scar in Descemet's membrane, shallowing or collapsing of the anterior chamber, scoring of the posterior corneal surface, snailtrack on endothelium, steroid rebound effect, striae in Descemet's, subconjunctival hemorrhage, thermal injury to adjacent eye tissues, toxic anterior shock syndrome, vitreous in the anterior chamber, vitreous band or loss, wound dehiscence, wound or incision leak, zonular dehiscence.

**CAUTION** Federal law (USA) restricts this device to sale by or on the order of a physician. The system should be used only by qualified physicians who have extensive knowledge of the use of this device and have been trained and certified.

**ATTENTION** Reference the Directions for Use for a complete listing of indications, warnings, and precautions.



# Why microscope-integrated OCT is vital to gene therapy applications

Confirming subretinal injection as opposed to suprachoroidal or sub-RPE injection is crucial

By Michelle Dalton, ELS

**INTRAOPERATIVE OPTICAL** coherence tomography (OCT) allows surgeons to visualize retinal anatomy and provides the surgeon with real-time feedback on instrument-tissue interaction.

Intraoperative microscope-integrated OCT can serve as confirmation for the surgeon that gene therapy injections have reached the subretinal space rather than the suprachoroidal space, said Ninel Z. Gregori, MD, associate professor of clinical ophthalmology, Bascom Palmer Eye Institute (BPEI), University of Miami Miller School of Medicine, Miami.

Finally, the use of intraoperative OCT can be helpful to monitor for possible complications, including an impending macular hole.

Gene therapy can be delivered via intravitreal injection or subretinal delivery, with the latter being more common (AAV and lentivirus vectors). However, these vectors do not penetrate the retina well and the vectors must be delivered subretinally if photoreceptor or retinal pigment epithelial (RPE) cells are targeted.

“These gene therapy products must transduce the photoreceptor or RPE cells,” she said.

Dr. Gregori and Janet Davis, MD, (also at BPEI) have performed 31 subretinal gene therapy surgeries since 2016. These have included phase I/II and phase III choroideremia trials (sponsored by Nightstar) and a phase I/II achromatopsia trial (sponsored by AGTC).

The two mentor each other, Dr. Gregori said, and now use their technique on 3 eyes undergoing voretigene therapy (voretigene is the first gene therapy to receive U.S. regulatory approval for the treatment of inherited retinal disorders).

“Confirming subretinal injection as opposed to suprachoroidal or sub-RPE injection is crucial for correct product delivery,” she said.

Injecting into the suprachoroidal space is more likely with very thin retinal and choroidal tissue seen in choroideremia.

At BPEI, microscope-integrated OCT (ReScan 700, Carl Zeiss Meditec) “has been used for

every gene therapy case by our surgical team since 2016,” she said.

The group published on their technique,<sup>1</sup> with video of three choroideremia patients undergoing a subretinal injection of adeno-associated viral serotype 2 vector (AAV2) encoding Rab-escort protein 1 (REP1) as part of a phase II clinical trial (NCT02553135).

The microscope-integrated OCT technique has been shown to assist visualization of the retinal microanatomy during the creation of a small subretinal bleb with balanced salt solution in preparation for subretinal viral vector injection.<sup>1</sup> Expansion of the subretinal bleb can then be directly observed as gene therapy is injected.

## ADVANTAGES OF MICROSCOPE-INTEGRATED OCT

Dr. Gregori said there are several advantages for surgeons who use these devices.

“First, there is the ability to raise subretinal bleb under direct microscope-integrated OCT guidance,” she said. “First, we assess, and then we inject virus into the space. Multiple instances of sub-RPE or suprachoroidal injections have thus been avoided.”

She said it’s common to see the subretinal pocket visualized, but also a suprachoroidal fluid pocket, so surgeons “must be sure the cannula containing virus goes into the subretinal fluid and that that pocket is enlarging as you’re injecting.”

Second, the technology has the ability to scan and determine the area and dimensions of subretinal blebs in order to ensure coverage of the therapeutic target zone.

“After scanning the macula, we ensure we use preoperative OCT

maps in order to inject and cover the area of interest,” she said.

Third, the technology can ensure the delivery of gene therapy is safe.

“It helps us avoid overstretching the fovea, avoid creating a macular hole, and avoid pre-existing macular holes or thin foveas while delivering the virus,” she said.

Macular holes are a potential complication “because you could lose all of your virus into the vitreous cavity,” she said. “We also avoid pre-existing macular holes and fovea while injecting virus, sometimes making a second bleb to cover the treatment target zone but avoiding creating a macular hole in an area of thinning.”

Pearls for gene therapy injection include moving gradually, avoiding overstretching the fovea, and ensuring the fovea remains intact.

Dr. Gregori described one case where the use of the microscope-integrated OCT identified a pending macular hole; the surgeons decided at that point to halt the procedure and create a second bleb in order to avoid a macular hole formation.

“We also try to avoid injecting air onto the retina,” she said. “Small bubbles don’t seem to cause issues, but larger air bubbles can cause tissue damage.”

Drs. Gregori and Davis recently published a video of their techniques using microscope-integrated OCT on the American Academy of Ophthalmology website, she said.

“This technology provides real-time feedback to guide viral vector injections and allows the detection of complications that may include incorrect layer injection or an impending macular hole that would otherwise not be visible,” she said.

Using microscope-integrated OCT “would likely make gene therapy accessible to more surgeons and clinical centers,” she said. ■

## Reference

1. Gregori NZ, Lam BL, Davis JL. Intraoperative use of microscope-integrated optical coherence tomography for subretinal gene therapy delivery. *Retina*. 2017;April 19. doi: 10.1097/IAE.0000000000001646

## NINEL Z. GREGORI, MD

E: [NGregori@med.miami.edu](mailto:NGregori@med.miami.edu)

This article was adapted from Dr. Gregori’s presentation at the 2018 meeting of the American Society of Retina Specialists. Dr. Gregori has no financial disclosures related to her comments.

## Take-home

► Using microscope-integrated optical coherence tomography would likely make gene therapy accessible to more surgeons and clinical centers, explains Ninel Z. Gregori, MD.

Supported by unrestricted grants from

REGENERON



# Progression to surgery for ERMs with good vision

Statistics help to counsel patients, allow them to make informed decision with specialist

By Xuejing (Jing) Chen, MD



## EDITOR'S NOTE

► Ophthalmology Times is pleased to recognize Xuejing (Jing) Chen, MD, vitreoretinal fellow, Tufts Medical Center, Ophthalmic Consultants of Boston, as the fifth-place honoree of the inaugural Ophthalmology Times Research Scholar Honoree Program. Dr. Chen's abstract is featured here.

The Ophthalmology Times Research Scholar Honoree Program is dedicated to the education of retina fellows and residents by providing a unique opportunity for fellows/residents to share notable research and challenging cases with their peers and mentors. The program is supported by unrestricted grants from Regeneron Pharmaceuticals and Carl Zeiss Meditec Inc.

To learn more about the program, go to [OphthalmologyTimes.com/2017RSH](http://OphthalmologyTimes.com/2017RSH)

## PURPOSE

In the United States, epiretinal membranes (ERMs) affect 30 million adults ages 43 to 86 years.<sup>1</sup>

The management for ERMs is observation for eyes with tolerable symptoms and surgical membrane peel for eyes with intolerable symptoms. Traditionally, surgery was reserved for eyes with vision 20/50 and worse or with absolutely intolerable symptoms, and patients with better vision were suggested to monitor. More recently, reports on surgery for symptomatic eyes with vision better than 20/50 or 20/60 have indicated favorable outcomes.<sup>2-5</sup>

These reports suggest that although eyes with good baseline vision have a smaller vision gain from preoperative to postoperative than eyes with worse baseline vision, the eyes with good vision tend to have a better absolute postoperative result, suggesting that advanced ERMs may contain a certain level irreversible vision loss.

For patients with good vision who can currently tolerate their symptoms, a common and important question is the risk of ERM progression. If progression to poor vision is certain within a short time period, then it behooves them to get surgery early and achieve a better absolute postoperative vision. However, if progression to poor vision or intolerable symptoms is prolonged, then the patient may choose to monitor as many are already of advanced age.

Few studies on the natural histories of ERMs exist. The Blue Mountain Study done in Australia showed that in ERM 1/3 progressed, 1/3 regressed, and 1/3 remained stable at 5 years.<sup>6</sup>

A study by Byon et al.,<sup>7</sup> looked at 62 eyes with good vision 20/40 or better and showed that less than 10% had a decrease in vision while 6.5% had an improvement in vision at 2 years. Our study elaborates on these works to look at the progression to surgery for eyes with good vision.

## METHODS

This is a retrospective, consecutive case series of all patients with newly diagnosed idiopathic ERMs referred to the Retina Service at the Ophthalmic Consultants of Boston between January 2009 and May 2012. Included eyes had 20/40 or better visual acuity without intolerable symptoms.

Eyes with baseline lamellar holes, baseline vitreomacular traction, secondary ERMs (e.g., from retinal detachment, vascular occlusions, uveitis), and the absence of baseline or final optical coherence tomography (OCT) were excluded.

Surgical membrane peeling was typically offered when vision worsened to 20/50 or beyond and/or when patients were unable to tolerate symptoms attributable to the ERM. Primary

	N	BASELINE VA
Overall	107	20/27
Normal Foveal Contour	24 (22%)	20/26
Mild Loss of Foveal Contour	26 (24%)	20/25
Loss of Foveal Contour	57 (53%)	20/29

(FIGURE 1) 107 eyes from 99 patients. Age 66 ±10 years.  
(Table courtesy of Xuejing (Jing) Chen, MD)

outcome measure was progression to surgery.

All eligible eyes were categorized by baseline OCT morphology into normal, mild or incomplete, and complete loss of foveal contour.

For the normal foveal contour category, signs of ERM presence must be noted on OCT including hyper-reflectivity overlying the macula or retinal corrugations, otherwise, the eye was excluded. Visual acuities were averaged through conversion to LogMar. Kaplan Meier survival curves for progression to surgical membrane peel were calculated.

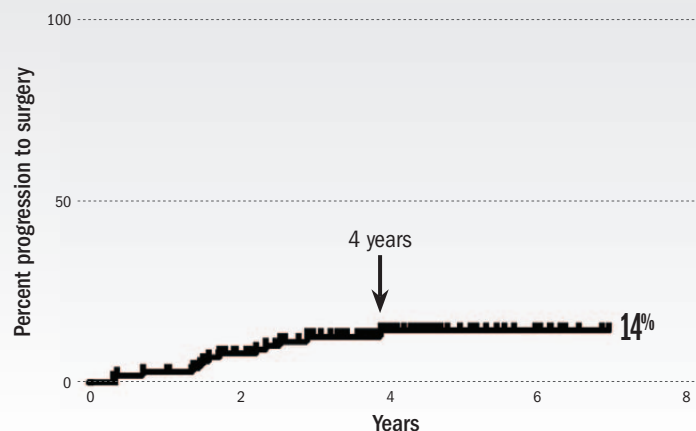
## RESULTS AND DISCUSSION

In all, 201 eyes from 170 patients were included in the study. Age averaged 67 years; 28.9% of eyes had normal, 17.4% had mild loss, and 44.3% had complete loss of foveal

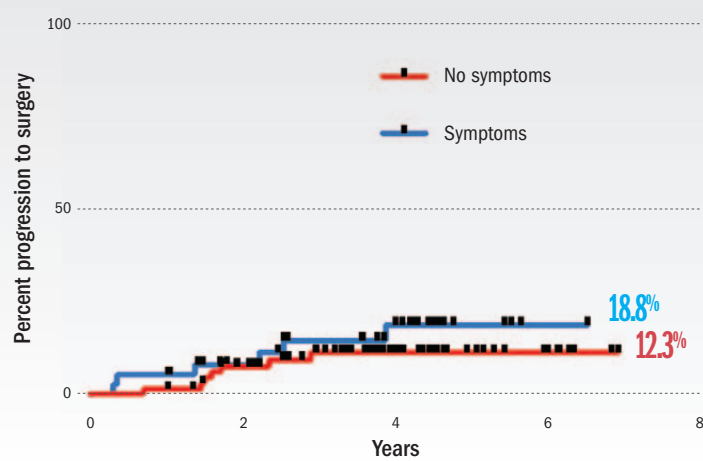
Continues on page 36 : Research Scholar

## RESEARCH SCHOLAR

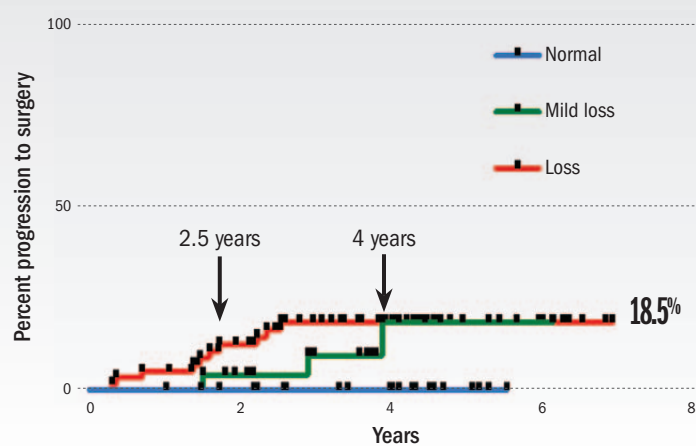
( Continued from page 35 )



**(FIGURE 2)** Kaplan Meier curve for progression to surgical membrane peel for all eyes. 14% of ERMs became sufficiently symptomatic for surgery at 7 years. No eyes progressed to surgery after 4 years.



**(FIGURE 3)** Kaplan Meier curve for progression to surgical membrane peel by presence of symptoms. Symptoms = blurry vision, metamorphopsia, diplopia. 18.8% of eyes with symptoms progressed to surgery; 12.3% of eyes without symptoms progressed to surgery ( $p = 0.34$ ).



**(FIGURE 4)** Kaplan Meier curve for progression to surgical membrane peel by baseline OCT morphology; 18.5% of eyes with mild loss of foveal contour and 18.5% of eyes with loss of foveal contour progressed to surgery by 7 years.

(Figures courtesy of Xuejing (Jing) Chen, MD)

contour. Average baseline visual acuity ranged from 20/28. Eyes with complete loss of foveal contour had statistically worse baseline visual acuity compared with eyes with normal and mild loss of foveal contour ( $p = 0.0001$ ).

Kaplan Meier survival curves show that 13% of ERMs with good vision progressed to surgery at 7 years.

Additionally, there appears to be a point in the curve at 4 years where eyes that had not progressed by this point, remain stable without surgery to 7 years.

When categorized by baseline OCT morphology, only 5% of eyes with normal foveal contour progressed to surgery by 5.5 years, whereas 17% of eyes with incomplete and 16% of eyes with complete loss of foveal contour progressed to surgery at 6 and 7 years, respectively.

Additionally, while the final rate of progression is similar between the latter two groups, eyes with complete loss of foveal contour appears to have a more rapid initial rate of progression that eventually converged with the incomplete loss of the foveal contour group.

Next, we looked at the survival curves categorized by the presence or absence of symptoms typically correlated with ERMs, such as blurry vision, metamorphopsia, and diplopia. A greater number of initially symptomatic eyes (15%) progressed to surgery compared with asymptomatic eyes (9%) at 7 years.

However, this visual trend was not statistically significant ( $p = 0.38$ ).

Our study is limited by its retrospective nature. The best available visual acuity was used as opposed to the best-corrected visual acuity.

Additionally, these are all eyes referred to a retina practice which may be a more selective population of eyes, presumably more ad-

vanced ERMs, than general ophthalmology practices, which would lead to an over-estimate of the progression rate.

Furthermore, most patients in this cohort deferred surgery until 20/50 or worse vision with a few opting for surgery with better vision but significant metamorphopsia. This preference trend may vary by patient population. In the absence of a more rigorous prospective study, our report offers data to this common clinical question posed by patients.

### CONCLUSIONS

In summary, 13% of ERMs referred to a retina practice with good vision became sufficiently symptomatic to consider surgery at 7 years. The progression of ERMs with good vision is associated with baseline OCT morphology, where no eyes with normal foveal contours progressed to surgery at 7 years and eyes with complete loss of foveal contour progressed faster than those with incomplete loss of foveal contour but the curves converge at 4 years. Eyes with symptoms did not have a statistically different progression to surgery as eyes without symptoms.

The purpose of this study is not to advocate for early or late surgery for ERMs with good vision, but rather to produce statistics to help counsel patients and allow them to make an informed decision with their retina specialists. ■

OT

For the complete article references, go to [ModernRetina.com/ERM](http://ModernRetina.com/ERM)

# Three financial metrics to drive practice performance

Why collection rates, days in A/R, and A/R aging analyses matter to your practice

By Gregory Cutrona

*"You can't manage what you don't measure."*

This is so true in so many things we do in everyday life. But this is especially true if you are a doctor today responsible for the management of a medical practice.

Unfortunately, too many physicians go to work every day unaware of how better reporting can drive higher performance of their medical practice.

The good news is by understanding three simple indices and metrics, any physician can begin to dramatically change the financial outcome of a medical practice and realize the return on investment of their efforts and an increased valuation of what is likely their most valuable asset.

## COLLECTION RATE

A collection rate is the measure of the practice's effectiveness in collecting all legitimate reimbursements. This takes into account the payers who the practice has contracted with and agree to write off the difference between the standard fee and the payer reimbursement rate.

By comparing the difference between the allowed amounts and actual reimbursements, a practice can determine how much is being lost to write-offs, untimely filing, non-contractual adjustments, and inferior collection practices.

Gross collection rate is calculated by dividing payments received from insurers and patients by gross charges. The gross collection rate can sometimes be misleading since most medical practices inflate charges billed to most insurers.

Net collection rate is calculated by dividing payments received from insurers and patients by allowed or contractual amounts. This is often more indicative of the physician's true collections performance. As an effective benchmark of the practice's financial health, it represents the percentage of reimbursement achieved out of the reimbursement allowed based on contractual obligations with payers.

Medical practices can also analyze their performance by looking at their net collections

by payer. If a medical practice sees unacceptably low net collections for a particular payer, it may consider alternatives such as requiring patients to pay up front for services or renegotiating payer contacts.

## DAYS IN

### ACCOUNTS RECEIVABLE

Days in accounts receivable (A/R) is an industry standard for measuring how many days amounts owed to the practice by insurance payers, patients, and third parties will take to be paid.

For example, if you see a patient today, days in A/R represent the average number of days it takes before you are fully paid for the services provided. The industry benchmark for this is typically 30 days but can vary by type of specialty and payer mix. This is one of the best single indicators of the performance of the revenue cycle and regular monitoring can provide insight into the efficiency of the revenue cycle.

Most practice management (PM) applications have built in capability to run a report for the desired timeframe, namely monthly, quarterly or yearly. If the PM application does not have the reporting capability, days in A/R can be calculated using the following formula:

$(\text{Total receivables} - \text{credit balance}) / \text{Average daily gross charges (Gross charges}/\#\text{days})$

For example:

Receivables = \$80,000  
 Credit balance = \$5,000  
 Gross charges = \$600,000  
 $[80,000 - (\$5,000)] / (\$600,000/365 \text{ days})$   
 $\$75,000/1644 = 45.62 \text{ days in A/R}$

In order to appropriately reflect the practice's performance, it is important to understand and consider some of the nuances that could have an impact on the result, such as carrier that are slower to pay, recognition of accounts in collection, and claims that have aged past 90 or 120 days. It is financially prudent to compute this metric with and without these categories so that performance is accu-

rately captured and not biased by factors that may negatively impact the finances.

## ACCOUNTS RECEIVABLE

### AGING

A/R aging analysis is a comparison of the actual accounts receivable aging to the expected accounts receivable aging. Disproportionate percentages indicate an inconsistent policy or procedure in how insurance payer and patient collections are being performed.

The proportion by percentage of the total amount of accounts receivable should be:

Percent of total A/R	Days
70%	0-30
10%	31-60
10%	61-90
10%	Over 90 days

Most PM applications can generate an A/R aging report that breaks down claims based on the number of days they have been unpaid, totaled by payer. This helps to identify potential issues from a high-level view so that you can prioritize how best to manage the A/R follow-up by dollar amount and by payer.

Days in A/R and A/R aging demonstrate a practice's ability to quickly turn over A/R and collect all money due.

The bottom line is: You can't know where you are going until you know where you are. Understanding the importance of your collection rate, days in A/R, and your accounts receivable aging is just the start to uncovering a breath of information that will put you on the path to higher medical practice performance. ■

**Editor's Note:** This article originally appeared on sister website, *MedicalEconomics.com*.

#### GREGORY CUTRONA

E: [admin@assurancemd.com](mailto:admin@assurancemd.com)

Gregory Cutrona is CEO of AssuranceMD.



# 'Hey Alexa, are you HIPAA compliant?'

Virtual assistants might seem a saving grace, but don't be fooled—they have much to learn

By Kevin K. Peek and Kyle Haubrich, JD

**IN A NOT-SO-DISTANT** past, people would look at me with expressions of concern as I attempted to verbally coerce my computer into not crashing as I submitted my term paper minutes before the deadline. While talking to inanimate objects used to be a sign for concern (unless you're David Hasselhoff accompanied by KITT from "Knight Rider"), nowadays it is an everyday occurrence for much of the population.

A significant majority of our personal electronics are embedded with virtual assistant software: Google's Google Assistant, Apple's Siri, and Amazon's Alexa among them. With these virtual assistants safely residing in our devices, we can speak to our phones, watches, computers, and now even our speakers. The final contender of that list has exploded in popularity over the last year. Smart speakers were the hottest items for the holiday season, especially thanks to Black Friday sales that lingered through the end of the holidays. With Apple missing out on the holiday sales earlier this year due to the delay of its HomePod smart speaker, Google and Amazon dominated the smart speaker sales boasting sales in the millions of their respective devices, according to industry estimates.

Smart speakers are capable of understanding and implementing tens of thousands of actions based on simple voice commands. The short list of these tasks includes creating shopping lists, playing songs by your favorite band, even turning on and off your lights, and adjusting your home's thermostat. Users can even purchase items simply by asking for it, and rest assured that their purchase is on its way by delivery. The list of tasks these smart speakers can manage is continuously growing.

While these devices were originally intended for home use, they have slowly trickled into our offices due to their massive potential and ability to keep track of calendar entries with a simple voice command. It goes without saying that many physicians and healthcare professionals will be tempted to utilize their functions for note taking, web research, or accessing medical records. But before you do, don't.

These virtual assistant programs are not yet in compliance with the Health Insurance Portability and Accountability Act (HIPAA).

The well-known goal of HIPAA is to protect patient protected health information. Private health information is the most sensitive, and incredibly under-secured, information in the world today. Ransomware hackers have increasingly targeted hospitals and physician offices for this reason. In particular, ransomware hackers focus their attacks on solo and small medical practices, because these practices tend to reduce spending on information technology, thereby becoming low-hanging fruit for sophisticated hackers.

Therefore, it is understandable that Alexa and Google Assistant need to jump through some more hoops before being allowed in a hospital room and access to medical records. Soon enough, Siri will need to follow their virtual steps. While Google and Amazon have worked on making their cloud services compliant with HIPAA's standards, neither smart speaker with their respective virtual assistant is HIPAA compliant at this time.

Physicians, hospitals, and practices should proceed—for the near term—as though Alexa, Siri, and Google Assistant are not HIPAA-compliant. Failure on the part of the physician to secure medical record data can not only cost them hundreds of thousands of dollars, but also enable thieves with the opportunity to commit identify theft.

## TAKE-HOME

► **Smart assistants like Alexa and Siri will need more manual and cloud-based security updates before they're HIPAA compliant.**

## POTENTIAL LOOMS, BUT CHANGE IS NEEDED

Virtual assistants must first be taught (i.e., programmed) to avoid mistakes and abuse related to healthcare. For example, if hospitals utilize Alexa to draft hospital notes and include the ability to make orders for procedures or medications, hospital procedures would need to be implemented to prevent anyone who is not a physician from walking into someone's room and creating an order. Also, if the smart speaker incorrectly "hears" the name of a medication and places an order for the wrong one, that would create obvious issues. Once the tech-

nology is more advanced and protections are in place, it will be up to hospitals to properly implement the voice-activated technology into the healthcare system.

This does not mean that your new, eager virtual assistant cannot be used for healthcare purposes. For example, getting your patient to use his or her smart home device to set a reminder to take medications at a certain time would be an acceptable use as it is a generic request. However, ordering a prescription for your patient through the service would be a violation, since personal information such as name, prescription, and home address would need to be provided. Asking Google to look up the definition of sphenopalatine ganglioneuralgia is acceptable; however, setting a reminder to tell patient Jane at her appointment that her headaches are caused by eating ice cream too quickly would be a HIPAA violation as this act would be synonymous with leaving a handwritten note with the same information out in your office lobby for anyone with a hint of curiosity to read.

While you may be tempted to bring your shiny new Amazon Echo, Google Home, or HomePod to your office, you would be well advised to keep your smart speaker at home for the time being until virtual assistance becomes well acquainted with HIPAA. Until then, try to stay content with asking your device to play "Dear Doctor" by the Rolling Stones to pass the time. ■

**Editor's Note:** This article originally appeared on sister website, [MedicalEconomics.com](http://MedicalEconomics.com)

**KEVIN PEEK** is an associate in the St. Louis office of Sandberg Phoenix focusing on cases involving medical malpractice defense and defense of providers in correctional healthcare.

**KYLE HAUBRICH, JD**, counsel at Sandberg Phoenix in St. Louis also contributed to this article.

For Products & Services and Recruitment advertising information, contact:  
**Joanna Shippoli** at 800-225-4569, ext 2615 • Fax 440-756-5271 • Email: joanna.shippoli@ubm.com

**PRODUCTS & SERVICES**

**BILLING SERVICES**



**P.M. Medical Billing Corp**  
 EXCLUSIVE OPHTHALMOLOGY BILLING AND CONSULTING

**Exclusive Ophthalmology Billers  
 Expert Ophthalmology Billers  
 Excellent Ophthalmology Billers  
 Triple E = Everything gets Paid**

**Concentrating on one Specialty makes the difference.**

We are a Nationwide Ophthalmology Billing Service. We have been in business over twenty years. Our staff consists of billers who are certified Ophthalmic Techs, Ophthalmic assistants, and fundus photographers who are dual certified ophthalmic coders and billers. This combination of clinical backgrounds in ophthalmology with the certified coding degree is the ideal combination of expertise that you need to dramatically increase your revenue. We will get you paid on every procedure every single time. No more bundling, downcoding or denials...

**Primary, Secondary, Tertiary and Patient Billing  
 Relentless and meticulous follow up.**

- Experts in Forensic Billing. Specializing in old AR cleanup
- Credentialing and Re credentialing our Specialty. We have a separate Credentialing Department who has cultivated years of contacts to expedite the process as well as getting providers on plans that are technically closed.
- We can offer you our own Practice Management software at no cost to you or we can VPN into your system if that is what you prefer.
- Totally Hipaa compliant. We are certified Hipaa and have invested in the most secure Hipaa connection that Google and Cisco use.
- Monthly custom reports provided.
- We do not outsource any of your billing. All billing done in our office in the U.S.A.

**We presently work on all of the following Practice Management systems :**

NextGen, MD Office, Centricity, Medisoft, Office Mate, MD Intellus, Medware, Medcomp, Management Plus, ADS, Revolution EHR, EyeMd EMR, Next Tec, Open Practice Solutions, Cerner Works and more....

All of our clients were paid the PQRI and E-prescribe bonuses and we are ready for the ICD-10 change

Our staff has years of Attendance at AAO and ASCRS and attends all ongoing Ophthalmology billing and Practice Management continuing education classes. We are always knowledgeable and prepared for all government and commercial changes.

On staff MBA consultants

Call today to schedule a free on site consultation.

We will travel to you anytime to evaluate your AR and show you how we can dramatically increase your Revenue.

**Call toll free at 1-888-PM-BILLING (1-888-762-4554)  
 Email: info@pmbiller.com • Web: www.pmbiller.com  
 24 hours: 516-830-1500**

Our Prestigious National Ophthalmology Clients reference list will be provided at your request

PM (Practice Management) Billing will keep an EYE on your Billing so you can keep an EYE on your patients.

**BILLING SERVICES**



Focused Medical Billing is a full service medical billing firm servicing all specialties of Ophthalmology. With our firm our focus is to maximize our client's revenue and dramatically decrease denials by utilizing 20 years of Ophthalmology billing/coding experience and expertise. Our firm provides accurate clean claim submissions on first submissions with relentless A/R follow up to obtain a 98% collection rate that so many of our clients enjoy.

**Services Include:**

- Expert Coders: Billing to Primary, Secondary & Tertiary insurance companies
- A/R Clean Up and analysis
- Patient Billing
- Posting of all Explanation of benefits
- Credentialing & Re-Credentialing
- Eligibility
- Fee Schedule Analysis
- Monthly Reports
- No long term commitment or contract required
- 100% HIPPA Compliant
- Stellar letters of reference

**NEW 2018 PROMOTION**

**Call us today for your free, no obligation consultation**

**Ph: 855-EYE-BILL ext. 802  
 Email: amay@focusedmedicalbilling.com  
 Web: www.focusedmedicalbilling.com**

*"You're focused on your patients, we're focused on you"*

**DIGITAL IMAGING**

**Carolina Ophthalmics**  
 got support?  
**TOPCON 50-EX/DX cameras  
 and Imagenet/OIS systems**  
**CALL US TODAY**  
**888.393.4624**  
 Imaging Specialists For Over 25 Years  
 www.imacam.net

**PRACTICE FOR SALE**

**Orlando Florida Area**  
**Solo ophthalmology practice for sale.**  
 Established 1980  
**3 equipped lanes with room for 4<sup>th</sup>**  
**Modern optical \$225k negotiable**  
**Details call Lyle 407-925-7450 Or**  
 email: [ocoeophthalmology@gmail.com](mailto:ocoeophthalmology@gmail.com)

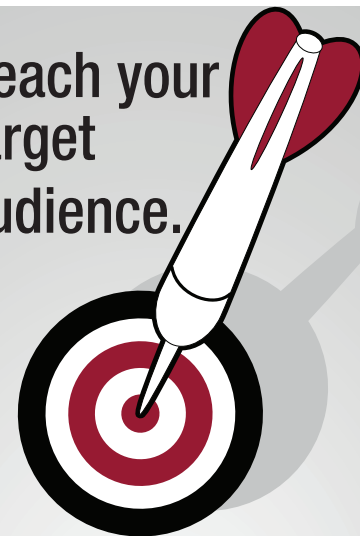**Recruitment Advertising  
 Can Work For You!**

Reach highly-targeted,  
 market-specific business  
 professionals, industry  
 experts and prospects by  
 placing your ad here!

**SPACE TO SHARE**

Ophthalmologist to share offices with long-established ophthalmologist in **Danbury, CT 06811. OCT, Zeiss Fieldmaster etc \$2,250/mo** or adjoining office without equipment **\$1,750/m. 203 545 3539, [mehrimd@aol.com](mailto:mehrimd@aol.com)**

Reach your target audience.



**Our audience.**

Ophthalmologists and allied eye care professionals. Contact me today to place your ad.

**Joanna Shippoli**

*Account Manager*

440-891-2773

[joanna.shippoli@ubm.com](mailto:joanna.shippoli@ubm.com)

**Ophthalmology Times**

# A guide to breaking down Medicare's high-cost prescription barriers

Physicians and patients can use app-based medication tools to improve adherence

By Parker Adams, Megan Gage, Colin Farritor, MBA, and Janis Coffin, DO, FAAFP, FACMPE

**HEALTHCARE COSTS** are continually on the rise. Between 1995 and 2015, U.S. healthcare spending grew at an annual rate of 4 percent, which far outpaces the annual economic growth rate of about 2.4%. Of this increase, a large contributor is the rising cost of prescription medication.

The U.S. pharmaceutical market is unique in that the manufacturer is able to set their drug costs at any price. This is in contrast to other nations with a national healthcare service, where the government is able to negotiate price and reject certain drugs for the entire nation. From 2013 to 2015, prescription medication spending increased roughly 20 percent to about 310 billion dollars, comprising 17 percent of healthcare cost in the United States. As care becomes more expensive, insurance companies must continually increase their prices in order to maintain coverage for their members. Consequently, patients are increasingly being priced out of receiving quality healthcare.

Simply put, this is unpleasant, unhealthy, and inefficient. Starting in 2019, Medicare will be using its Merit-based Incentive Payment System (MIPS) to reimburse medical practices and individual providers for care. Among the incentives being measured are quality of care and clinical improvement. As patient adherence drops, so could quality of care, patient satisfaction and physician reimbursement.

So what can a physician do if a patient is non-adherent due to the cost of prescription medications? Here are a number of ways a physician can work with their patients to best overcome cost barriers, and different ways a practice can integrate these processes into their workflow.

## TOOLS

Prescribing generics is the first way to help patients afford their medications. Walmart's Four Dollar Generic List is a great resource for

physicians to utilize. There are also apps for physicians that will allow them to compare effectiveness and side effects of generic medications to their name brand counterparts. Epocrates is a well-known application that has a feature enabling physicians to compare safety information and prescribing details for many name brand, OTC, and generic medicines.

Additionally, there are many apps that patients may find useful. Some of the top-rated apps available on computer and mobile devices are OneRX, GoodRX, and LowestMed. These apps help patients find discounts on their name brand or generic prescriptions, compare prices at different pharmacies, and will work to include their insurance plan so the user can see what the cost will be based off their coverage. These apps offer a lot of the same benefits, but GoodRX seems to be the app with the most features. It has reminders built in to refill prescriptions, shows where the \$4 generics are, and can even find pharmacies that have some generics for free.

For patients who have a Medicare Advantage health plan or a Part D prescription plan, CMS offers medication therapy management in which patients receive one-on-one counselling sessions with a pharmacist at no cost. During these sessions the pharmacist reviews how to take each medication and checks for duplications or negative drug interactions.

Even with all of these resources, some patients may still not be able to pay for their medications. For them, a patient-assistance program (PAP) may be an additional option. Pharmaceutical companies have funded PAP programs to help cover patients' copayments, coinsurance, and deductibles. Medicare.gov lists information for many of these programs, and each is specific to a certain medication.

If additional aid is necessary, state-funded and non-profit programs like NeedyMeds are available to help patients. It is important to

remember that even an insured patient may still have trouble paying for medications. A situation that often arises with the Medicare Part D coverage gap.

## INTEGRATION INTO PRACTICE WORKFLOW

The time commitment to integrate these tools into a practice's workflow may seem daunting. Because of this, a model for where to spend time and effort is ideal so that prescription cost and clinician effort can both be minimized. Table 1 below shows a progression of intervention and how the steps can work with each other depending on how the patient is managing the cost of the prescription medication.

Description	Action
Adherent	Generics when possible
Cost sensitive + adherent	Patient apps
Cost annoyance + non-adherent	Insurance council referral Clinical apps
Inability to pay	PAPs State-funded programs Non-profits

First, generics should be used whenever possible. If a patient is adherent, but has a concern about the cost, directing the patient to the common apps they can use could be an easy, beneficial step. Up to this point, cost management has minimally impeded daily operations.

Physician and/or healthcare team efforts increase slightly when the patient becomes non-adherent due to a medication's cost. This is because as soon as the patient is non-adherent, there is a drop in the quality of care. If it is available, a referral to someone within the clinic or a part of the hospital system to counsel the patient on their insurance coverage could help this patient's adherence. At this stage, it is also necessary to analyze the patient's prescription at a deeper level. Could the side effects of a different generic be tolerated for adherence? Having a patient-centered approach and discussing the risks and benefits, including cost, will increase patient adherence,

## TAKE-HOME

► **As healthcare costs climb higher, patient adherence drops. Work closely with your patients by using prescription cost apps, prescribing generics, or employing the use of PAPs programs.**

## Toolbox:

### WALMART'S \$4 GENERIC LIST

<https://www.lowestmed.com/walmart-4-dollar-list/>

### PHYSICIAN APPS

<http://www.epocrates.com/products/features>

### PATIENT APPS

<https://onerx.com/>

<https://www.goodrx.com/>

<https://www.lowestmed.com/>

### INSURANCE QUESTIONS

<https://www.medicare.gov/find-a-plan/questions/home.aspx>

### MEDICATION THERAPY MANAGEMENT

<https://www.medicare.gov/part-d/coverage/medication-therapy-management/medication-therapy-programs.html>

### PAP PROGRAMS

<https://www.medicare.gov/pharmaceutical-assistance-program/Index.aspx>

### STATE PROGRAMS AND FURTHER ASSISTANCE

<https://www.medicare.gov/pharmaceutical-assistance-program/state-programs.aspx>

<https://www.medicare.gov/your-medicare-costs/help-paying-costs/save-on-drug-costs/save-on-drug-costs.html>

quality of care and overall patient satisfaction.

The next level of involvement is a patient who is able to afford to buy the prescription some months, but not all the time. This is when the physician and/or the healthcare team can begin introducing the Patient Assistant Programs.

For everyone involved, it will take some time to become familiar with these programs. Just like a physician has a few drugs that they use consistently for hypertension, the same goes for PAP programs. Do not become overwhelmed with all of the possible options, simply pick a few drugs that are common budget breakers and understand their respective programs. The number of programs utilized can always be expanded over time. At this stage, also introduce the patient to state assistance programs that are available to them. Similar to the PAPs,

make this simple and streamlined. Involving others in the healthcare team can also lighten the load and make this process more efficient.

The last level of cost management is a patient that is non-adherent due to complete inability to pay for medications. They can't afford the prescription, they never could afford the prescription, and they won't be able to afford it in the foreseeable future. These patients need everything in the toolbox. Engage the PAPs and state programs. Finally, see if the patient is a candidate for any assistance programs available through non-profit organizations.

### DRIVING DOWN COSTS

An estimated 50 percent of medications for chronic disease are not adhered to as prescribed. Although this lack of adherence is not always

a cost issue, the price of medications can be a heavy burden on patients. Segmenting the patient population according to their ability to afford their prescription medications allows for more affordable care and an increase in patient adherence, which increases the quality of care. The first few steps are easy and take very little time to put into action. The last few steps may require more time, but it doesn't have to be just a one-person job. Splitting up the work among the healthcare team can accomplish the same outcomes.

The front desk personnel, social worker, nurses, and others can all contribute to this process of patient education and support. If the physician is the only one that knows about the programs and assistance methods, they are the only ones that can educate. The American Academy of Family Physicians suggests bringing on a weekly volunteer to assist in organizing the PAPs for the patients.

Being diligent in helping the patient population be adherent will not only improve the patient's health, but their satisfaction. It will also decrease the overall burden on the healthcare system, lowering cost per capita, and stabilize physician reimbursement going forward. ■

**Editor's Note:** This article originally appeared as a blog on sister website, *MedicalEconomics.com*. The opinions expressed here are that of the authors and not UBM/Medical Economics or Ophthalmology Times.

**PARKER ADAMS, MEGAN GAGE, AND COLIN FARRITOR, MBA,** are first-year osteopathic medical students at Kansas City University of Medicine and Biosciences in Joplin, MO.

**JANIS COFFIN, DO, FFAFP, FACMPE,** is a professor in the department of family medicine at Kansas City University of Medicine and Biosciences in Joplin, MO.

## Aqueous humor gene mutation may detect vitreoretinal lymphoma

**ULTRA-SENSITIVE** droplet digital polymerase chain reaction (ddPCR) is a potential new biopsy tool to diagnose and monitor vitreoretinal lymphoma (VRL), new research from the Netherlands suggests.

Aqueous humor paracentesis can detect MYD88 L265P gene mutations in the aqueous humor (AH) of patients with vitreoretinal lymphoma and is relatively less invasive and safer than taking vitreous fluid (VF) specimens, the authors write in *JAMA Ophthalmology*, online July 19.

"This approach may provide a valuable ad-

ditional tool for minimally invasive liquid biopsy analysis of patients suspected of having VRL," they write. "As molecular techniques are evolving rapidly, this may enable the role of AH analysis in routine diagnostic workup of patients who are presenting with a differential diagnosis, including VRL."

Laura S. Hiemcke-Jiwa, MD, of University Medical Center Utrecht and colleagues investigated the presence of the MYD88 L265P mutation in aqueous humor and vitreous fluid detected by a validated ddPCR assay technique the research team had developed.

The study involved 23 patients with VRL and 40 with uveitis included as a comparison group who were treated at one academic treatment center from 2005 to 2017. They averaged 72 years of age in the VRL group and 52 in the uveitis group.

After treatment, the mutation could not be detected in either AH or VF.

"The genetic profiling of VRL also offers an interesting therapeutic potential, which is still in the investigative stage," they add.

The study had no commercial funding and the authors reported no conflicts of interest. ■

# Seeing dollar signs won't improve your vision



Artwork by Jon Carter

## Advertiser Index

Advertiser	Page
<b>AGTC</b> https://agtc.com 617/843-5728	<b>CV4</b>
<b>Bausch + Lomb</b> www.bausch.com 800/227-1427	<b>CV2</b>
<b>Doheny Eye Institute</b> www.doheny.org/cme 323/442-6427	<b>CV3</b>
<b>Shire Ophthalmic</b> www.shire-eyes.com 800/828-2088	<b>4-6</b>

This index is provided as an additional service. The publisher does not assume any liability for errors or omissions.

**OPHTHALMOLOGY TIMES** (Print ISSN 0193-032X, Digital ISSN 2150-7333) is published semi-monthly except for one issue in Jan, May, Aug and Dec (20 issues yearly) by UBM LLC, 131 W First Street, Duluth, MN 55802-2065. Subscription rates: \$200 for one year in the United States & Possessions, Canada and Mexico; all other countries \$263 for one year. Pricing includes air-expedited service. Single copies (prepaid only): \$13 in the United States & Possessions, Canada and Mexico; \$20 all other countries. Back issues, if available are \$25 in the U.S. \$ Possessions; \$30 in Canada and Mexico; \$35 in all other countries. Include \$6.50 per order plus \$2 per additional copy for U.S. postage and handling. If shipping outside the U.S., include an additional \$10 per order plus \$5 per additional copy. **Periodicals postage paid** at Duluth, MN 55806 and additional mailing offices. **POSTMASTER:** Please send address changes to OPHTHALMOLOGY TIMES, P.O. Box 6009, Duluth, MN 55806-6009. Canadian G.S.T. number: R-124213133RT001, Publications Mail Agreement Number 40612608. Return undeliverable Canadian addresses to: IMEX Global Solutions, PO Box 25542 London, ON N6C 6B2 CANADA. Printed in the U.S.A.

© 2018 UBM. All rights reserved. No part of this publication may be reproduced or transmitted in any form or by any means, electronic or mechanical including by photocopy, recording, or information storage and retrieval without permission in writing from the publisher. Authorization to photocopy items for internal/educational or personal use, or the internal/educational or personal use of specific clients is granted by UBM for libraries and other users registered with the Copyright Clearance Center, 222 Rosewood Dr. Danvers, MA 01923, 978-750-8400 fax 978-646-8700 or visit <http://www.copyright.com> online. For uses beyond those listed above, please direct your written request to Permission Dept. fax 732-647-1104 or email: [Jillyn.Frommer@ubm.com](mailto:Jillyn.Frommer@ubm.com)

## in case you missed it

How retinal surgeons are practicing in 2018 **PAGE 8**

Targeted therapy may be on horizon for ocular melanoma **PAGE 21**

Understanding achromatopsia, a rare inherited retinal disease **PAGE 27**

'Hey Alexa, are you HIPAA compliant?' **PAGE 38**

## next issue...

► The neuro-ophthalmic manifestation of autoimmune disorders

► Special Report: The new wave of diagnostic technology



Host a summer optical event!

[OPHTHALMOLOGYTIMES.COM/SUMMEREVENT](http://OPHTHALMOLOGYTIMES.COM/SUMMEREVENT)

7 ways to 'hack' your EHR

[OPHTHALMOLOGYTIMES.COM/EHRHACKS](http://OPHTHALMOLOGYTIMES.COM/EHRHACKS)



# 3rd Annual International Glaucoma Symposium

The course material will be a combination of anterior and posterior segment clinical scenarios, translational research, and bench investigation.

## TOPICS

- Glaucoma pharmaceuticals (including new FDA-approved drugs)
- New outflow concepts for the trabecular and uveoscleral pathways
- Structural imaging and functional assessment synergy
- Surgical experience (from minimally invasive glaucoma surgeries to cataracts/glaucoma surgery to clinical trials results for glaucoma shunts)
- New clinical practice regulatory requirements
- IRIS registry

## Saturday, November 17

## REGISTER NOW

[www.doheny.org/cme](http://www.doheny.org/cme)

Earn Up to 8 AMA PRA Category 1 Credits™ | Complimentary Registration

### Course Director



#### Alex Huang, MD, PhD

Assistant Professor of Ophthalmology  
David Geffen School of Medicine, UCLA  
Doheny Eye Institute

**Saturday, November 17 | 7:30am to 5:00pm**

Moseley Salvatori Conference Center  
Good Samaritan Hospital  
637 South Lucas Ave.  
Los Angeles CA 90017

### Featured Course Faculty



#### Donald L. Budenz, MD, MPH

Kittner Family Distinguished Professor  
Chairman of the Department of Ophthalmology  
University of North Carolina, Chapel Hill

For more information, contact the  
Doheny CME office at (323) 342-6427  
or email [cme@doheny.org](mailto:cme@doheny.org).



#### David Garway-Heath, MD, FRCOphth, FARVO

President of European Glaucoma Society  
IGA Professor of Ophthalmology for Glaucoma and Allied Studies  
University College London Institute of Ophthalmology  
Moorfield's Eye Hospital, London, UK



Office of Continuing Medical Education



#### Neeru Gupta, MD, PhD, MBA

Professor and Dorothy Pitts Chair  
Chief of Glaucoma, University of Toronto  
Director, Glaucoma Unit and Research Program  
Keenan Research Centre for Biomedical Science  
Li Ka Shing Knowledge Institute, Canada

**Earn Up to 8 AMA PRA Category 1 Credits™**

**Accreditation Statement:** Doheny Eye Institute is accredited by the Institute for Medical Quality/California Medical Association (IMQ/CMA) to provide continuing medical education for physicians.

**Credit Designation Statement:** Doheny Eye Institute designates this live activity for 8 AMA PRA Category 1 Credits™. Physicians should only claim credit commensurate with the extent of their participation in the activity.



## The answer to genetic blindness begins with a **CLEAR VISION**

Clinical trials are underway to evaluate potential gene therapy treatments for inherited retinal disorders:

### **X-LINKED RETINITIS PIGMENTOSA (XLRP) AND ACHROMATOPSIA (ACHM)**

There is **no cure** or approved treatment for these conditions.



**AGTC, a clinical-stage biotechnology company**, is sponsoring a Phase 1/2 clinical study to evaluate the safety and efficacy of an investigational gene therapy in patients with XLRP caused by mutations in the RPGR gene, and two separate Phase 1/2 clinical studies of investigational gene therapies in patients with Achromatopsia caused by a mutation in either the CNGB3 or CNGA3 genes.

#### **Key inclusion criteria for the XLRP clinical trial:**

- Male aged 6 years and older
- Confirmed clinical diagnosis of XLRP and a documented mutation within the RPGR gene (genetic confirmation will be obtained prior to enrollment)

For detailed information, refer to [www.clinicaltrials.gov](http://www.clinicaltrials.gov)  
Identifier No. NCT03316560

#### **Key inclusion criteria for the ACHM CNGB3 clinical trial:**

- Age 6 years and older
- Confirmed clinical diagnosis of Achromatopsia with documented mutation in both alleles of the CNGB3 gene (genetic confirmation will be obtained prior to enrollment)

For detailed information, refer to [www.clinicaltrials.gov](http://www.clinicaltrials.gov)  
Identifier No. NCT02599922

#### **Key inclusion criteria for the ACHM CNGA3 clinical trial:**

- Age 6 years and older
- Confirmed clinical diagnosis of Achromatopsia with documented mutation in both alleles of the CNGA3 gene (genetic confirmation will be obtained prior to enrollment)

For detailed information, refer to [www.clinicaltrials.gov](http://www.clinicaltrials.gov)  
Identifier No. NCT02935517

Without **clinical research**, there can be no new treatments.

For more information, and to see whether any of your patients qualify to join the study, visit [www.agtc.com/clinical-studies](http://www.agtc.com/clinical-studies) or contact us at [advocacy@agtc.com](mailto:advocacy@agtc.com).

To learn more about AGTC, please visit [www.agtc.com](http://www.agtc.com).